


骨髓活检在淋巴瘤诊断中的意义

中国医学科学院
血液病医院
汝昆

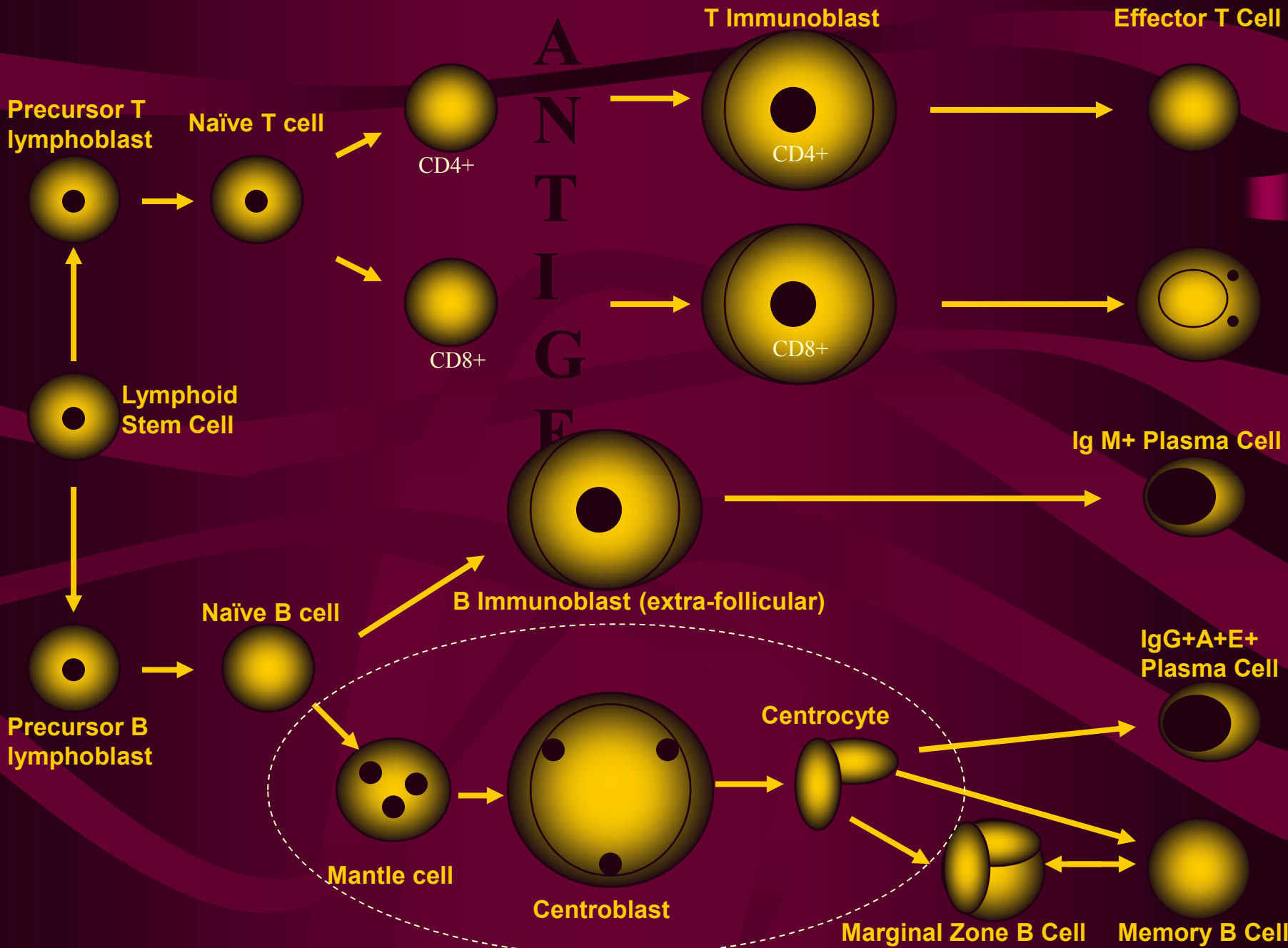
kunru@yahoo.com






淋巴瘤的分类

- 淋巴瘤的分类试图对应**正常**淋巴细胞的发育过程
- 每一类淋巴瘤可视为淋巴细胞**停滞**在发育的某个阶段并进而转化为恶性细胞
- 淋巴瘤中**85%**是**B**细胞来源，其余的为**T**或者**NK**细胞



血液肿瘤



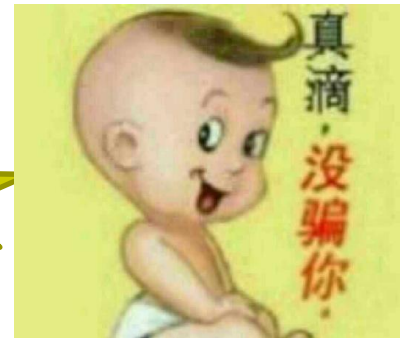1. 骨髓增殖性肿瘤 (MPN): 12 (亚)型
2. 骨髓异常增殖性疾病 (MDS): 8 型
3. MPN/MDS: 4 型
4. 淋巴类肿瘤伴嗜酸性细胞增多和PDGFRA, PDGFRB, or FGFR1异常
5. 急性髓系白血病 (AML): 24 (亚)型
6. 急性淋巴系白血病 (ALL): 9 (亚)型
7. 分化不清的急性白血病 (ALAL): 7 型
8. 成熟B细胞淋巴瘤: 33 (亚)型
9. 成熟T细胞淋巴瘤: 20 (亚)型
10. Hodgkin淋巴瘤: 5 (亚)型
11. 免疫相关的淋巴增殖性疾病: 7 (亚)型
12. 组织细胞和树突细胞肿瘤: 7 (亚)型


24

40

53

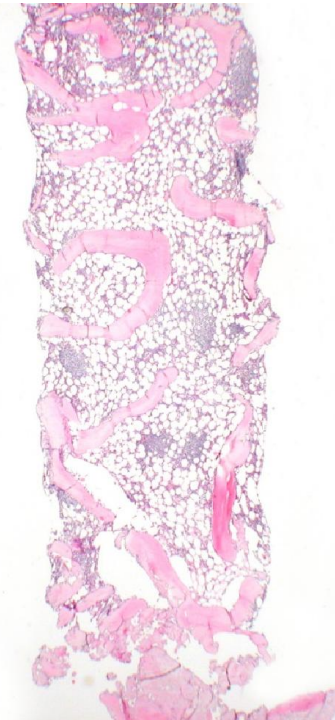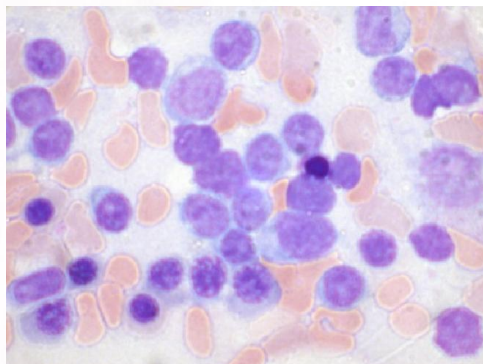
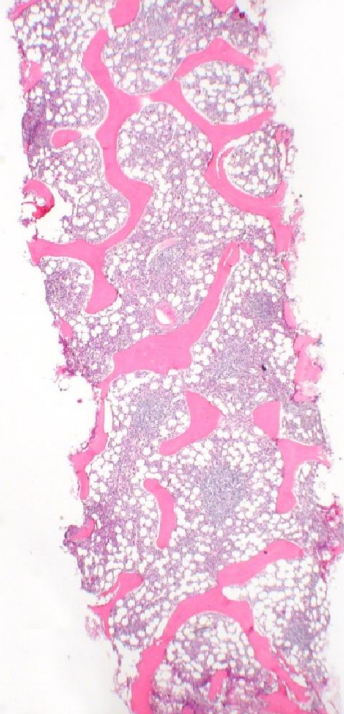
19





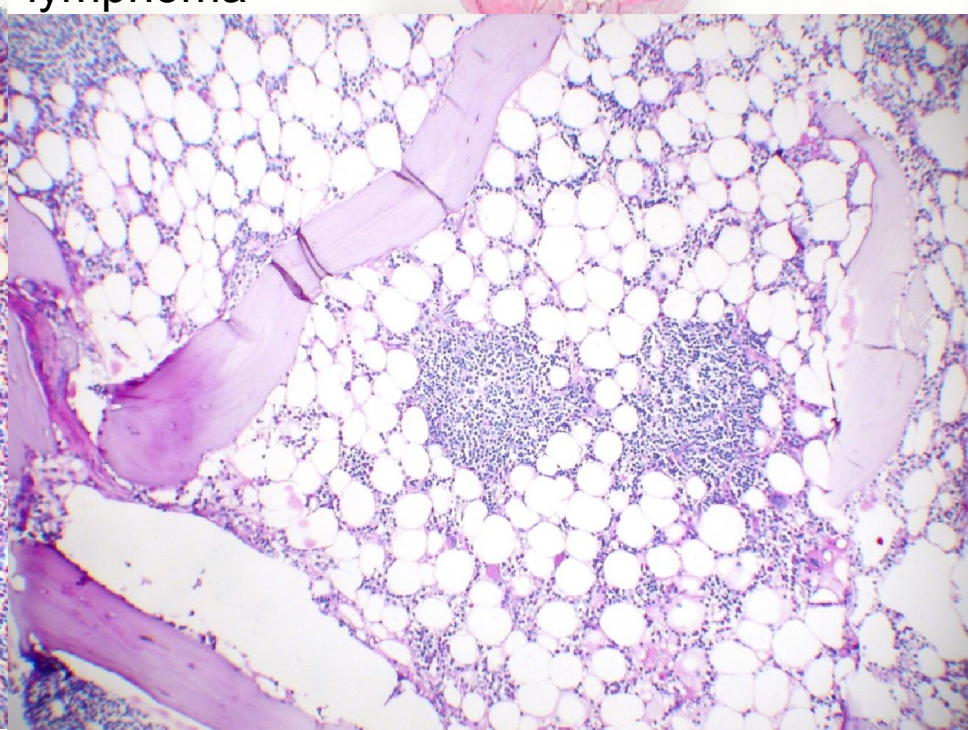
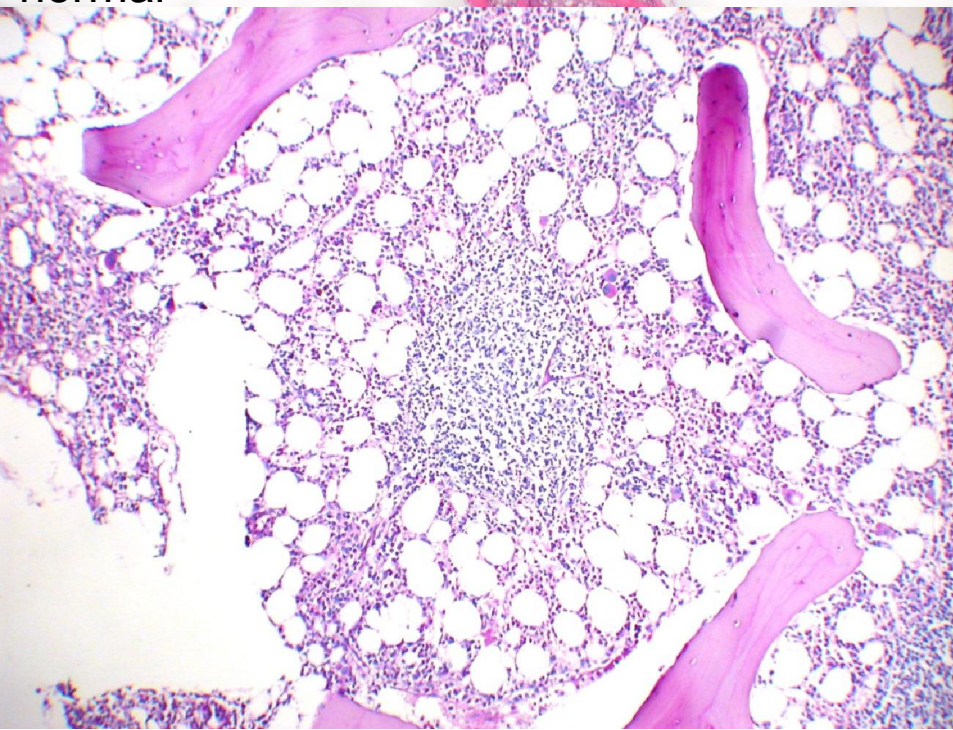
诊断 分期

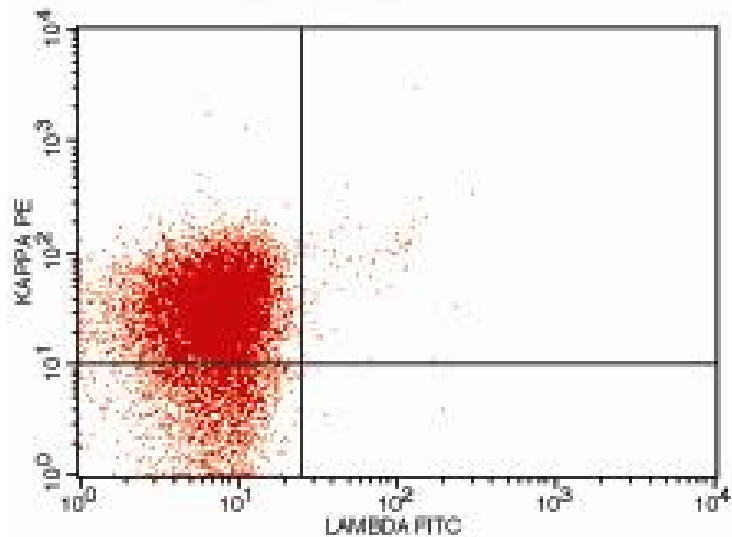




lymphoma

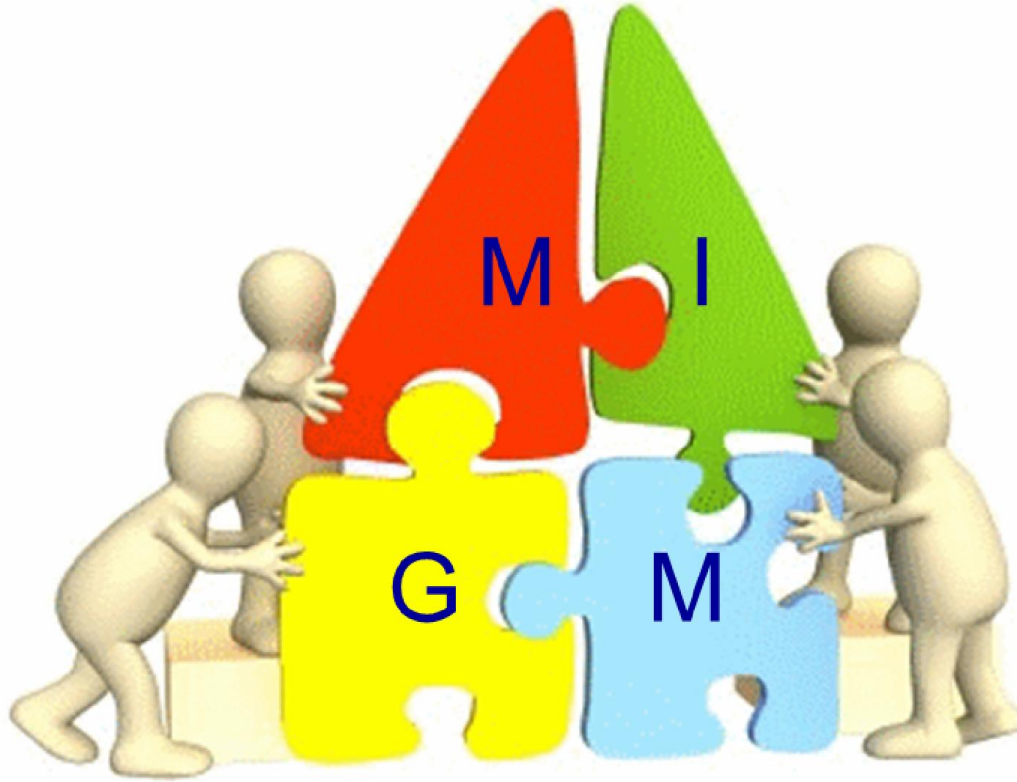
normal





Dye/Sample Peak	Sample File Name	Marker	Allele	Size	Height	Area	Data Point
G,43	42_G05_013.fsa			251.29	40		4103
G,44	42_G05_013.fsa			257.64	2192	11424	4189
G,45	42_G05_013.fsa			258.83	219	1964	4205

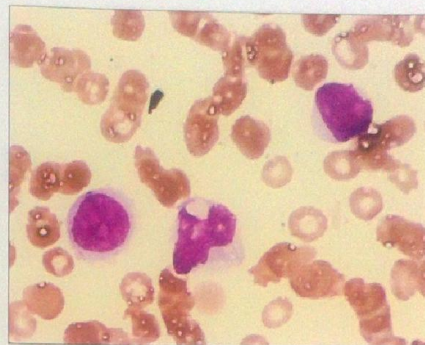
中国医学科学院 血液病医院 血液学研究所



中国医学科学院血液病医院
细胞形态室骨髓细胞形态学检查图文报告单

年龄 92 性别 男 科室 急诊科 床号 _____ 采集时间 2013-08-21 20:23
 59080 标本编号 会诊 病案号 333606 样本类型 髂骨 开单医生 _____
 2013-08-21 20:23 报告时间 2013-08-22 20:24 临床诊断 急性白血病? 备注 _____

血片%	骨髓片		
	平均值	+/-SD	%
	0.08	0.01	
胞 1	0.64	0.33	2.0
胞 1	1.57	0.6	3.5
幼 2	6.49	2.04	7.0
幼 8	7.9	1.97	10.0
核 23	23.72	3.5	24.5
核 28	9.44	2.92	8.0
幼	0.38	0.23	
幼	0.49	0.32	
核	1.25	0.61	
核	0.86	0.61	
幼	0.02	0.05	
幼	0.06	0.07	
核	0.1	0.09	
核	0.03	0.05	
包	0.57	0.3	
包	0.92	0.41	
包	7.41	1.91	2.0
包	10.75	2.36	9.5
	0.05	0.09	
	0.47	0.84	
13	22.78	7.04	12.5
	0.01	0.04	
4	0.14	0.19	4.0
20	3	0.88	16.0
	0.004	0.02	
	0.104	0.16	
	0.71	0.42	1.0
	0.05	0.09	
	0.03	0.09	
	2.76	0.87	4.78/1
100	个		200



形态描述:


(一)骨髓涂片细胞学检查

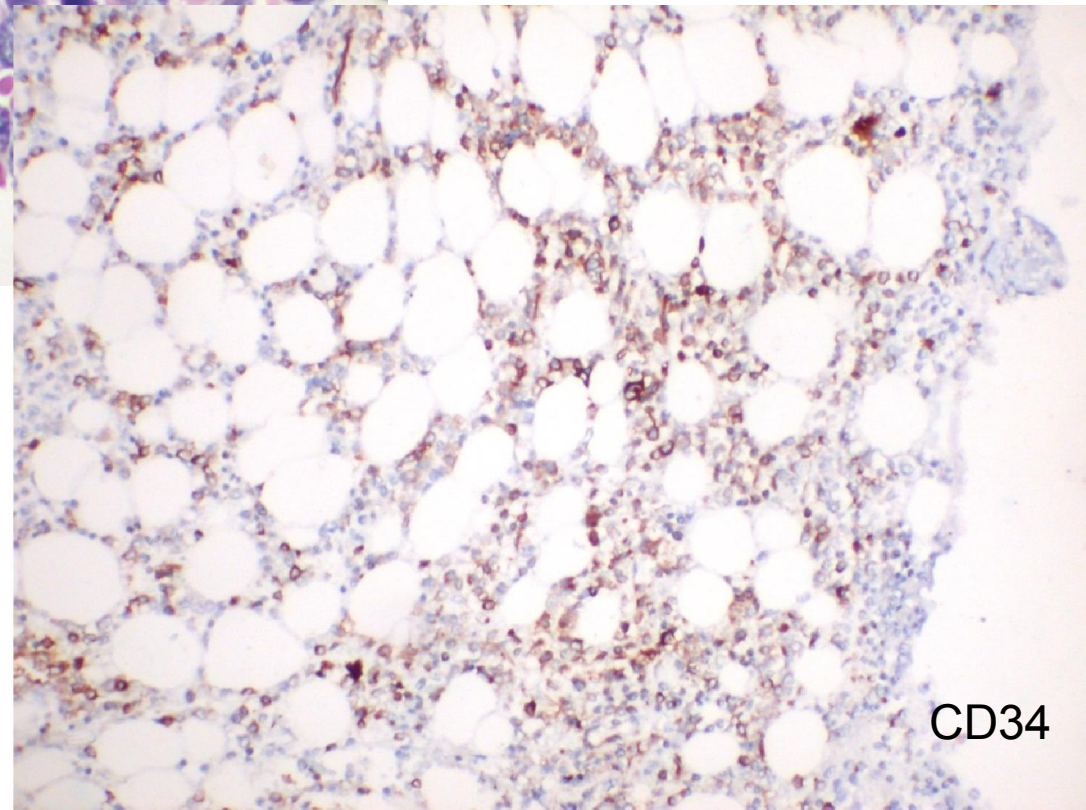

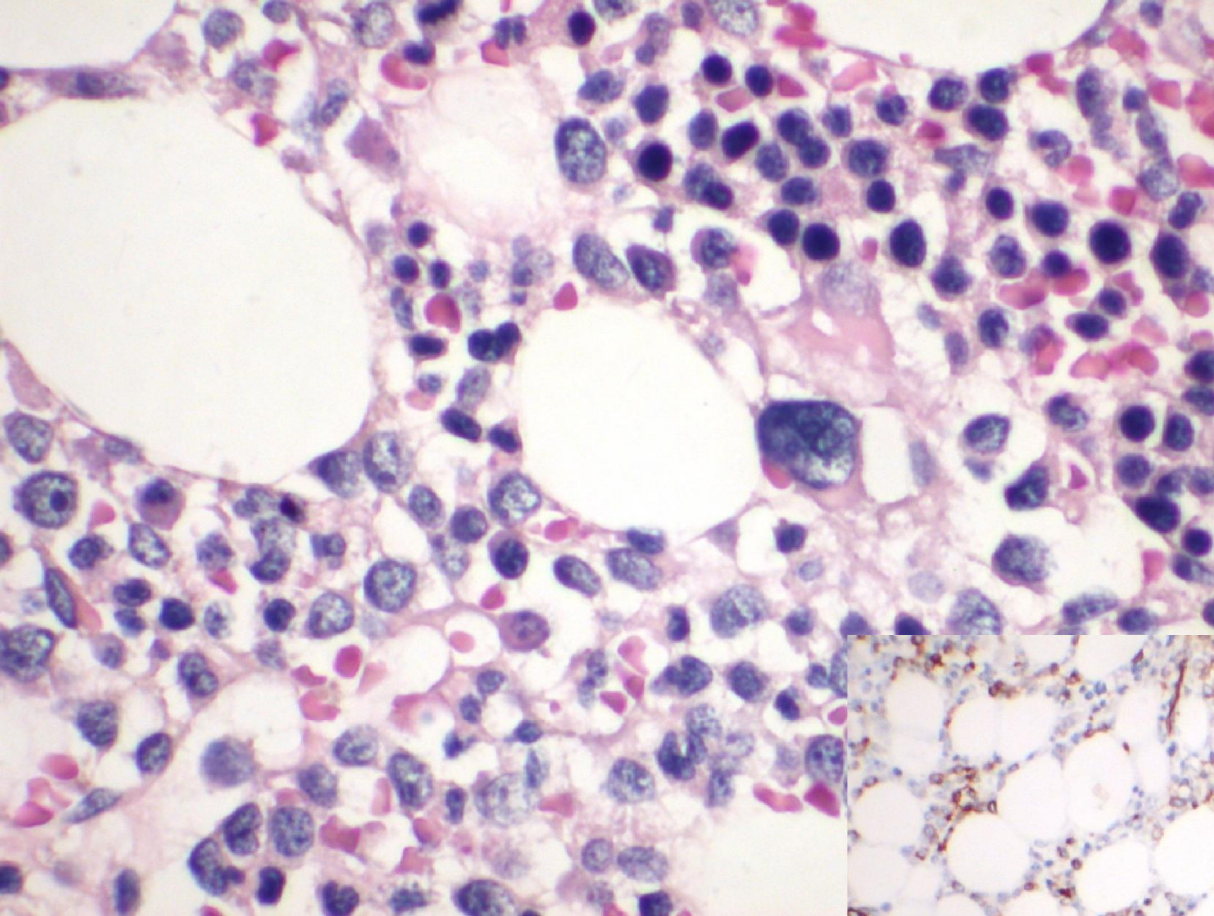
- 取材、涂片、染色良好。粒(+)油(+)
- 增生减低，G=59%，E=11.5%，G/E=5.13/1。
- 粒系比例正常，部分粒细胞胞浆内可见空泡，偶见双核粒。可见假性P-H畸形
- 红系比例减低，以中晚幼红为主。部分成熟红细胞边缘不整齐，中心淡染区扩大。
- 淋巴细胞比例正常，形态无明显异常。单核细胞系比例增高，可见幼稚单核细胞。
- 全片共见巨核细胞6个。其中成熟无血小板形成巨核细胞2个、裸核4个。血小板少见。

(二)外周血细胞形态学分析

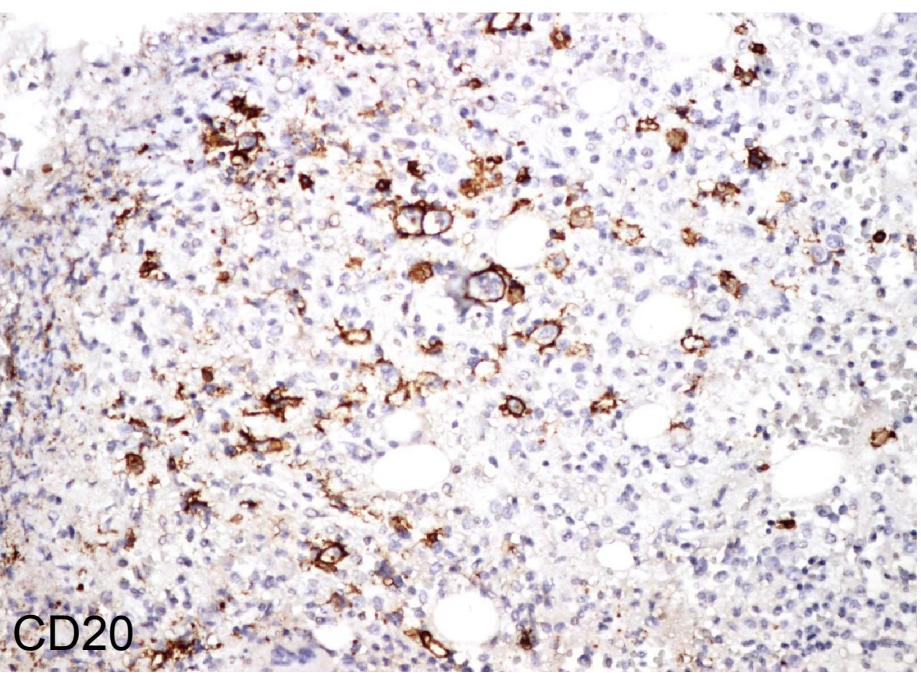
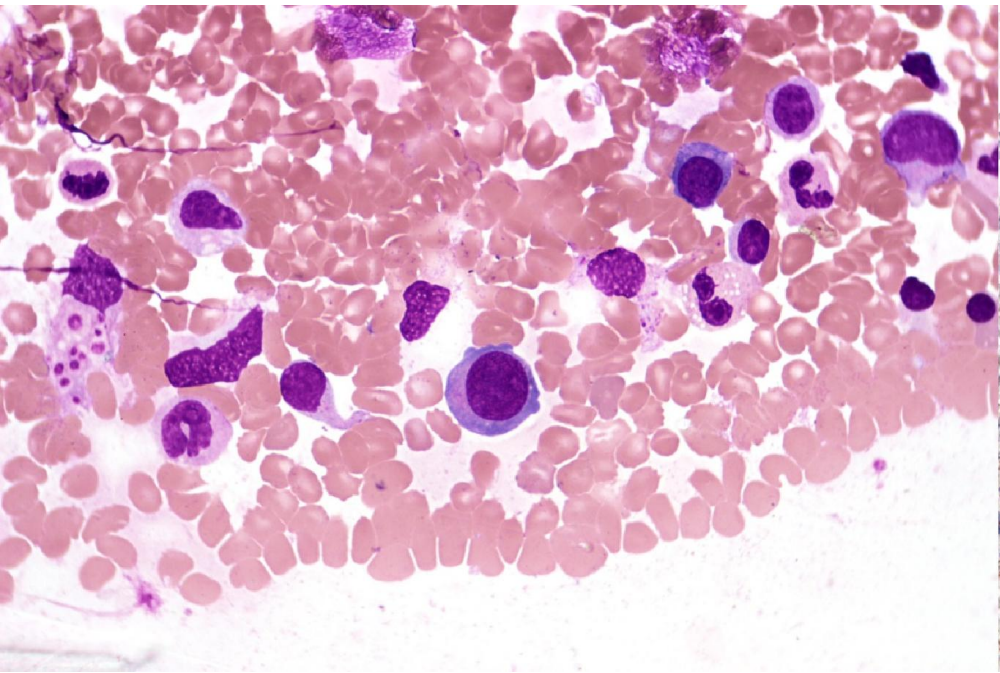
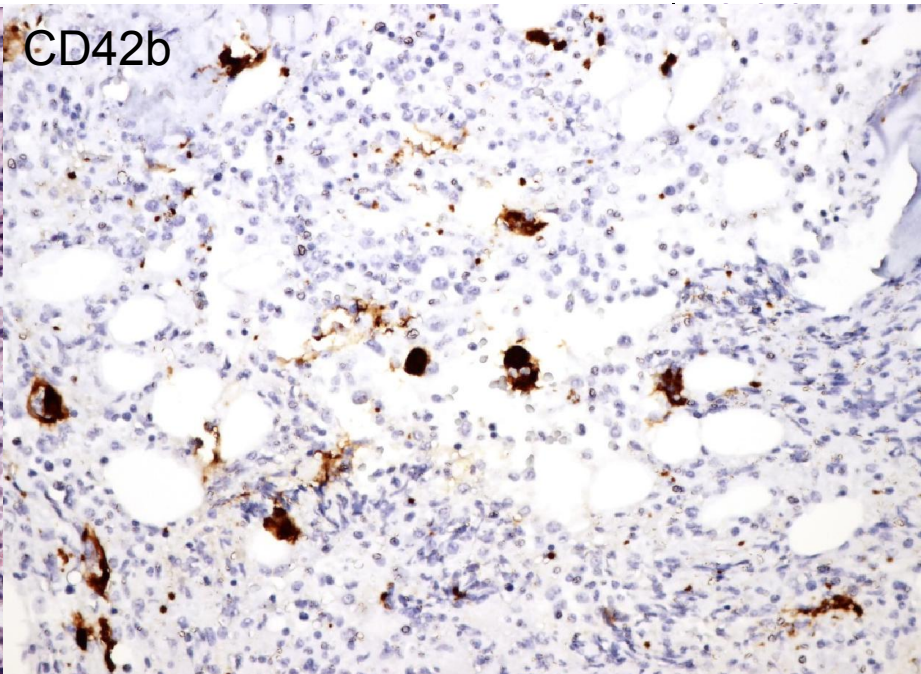
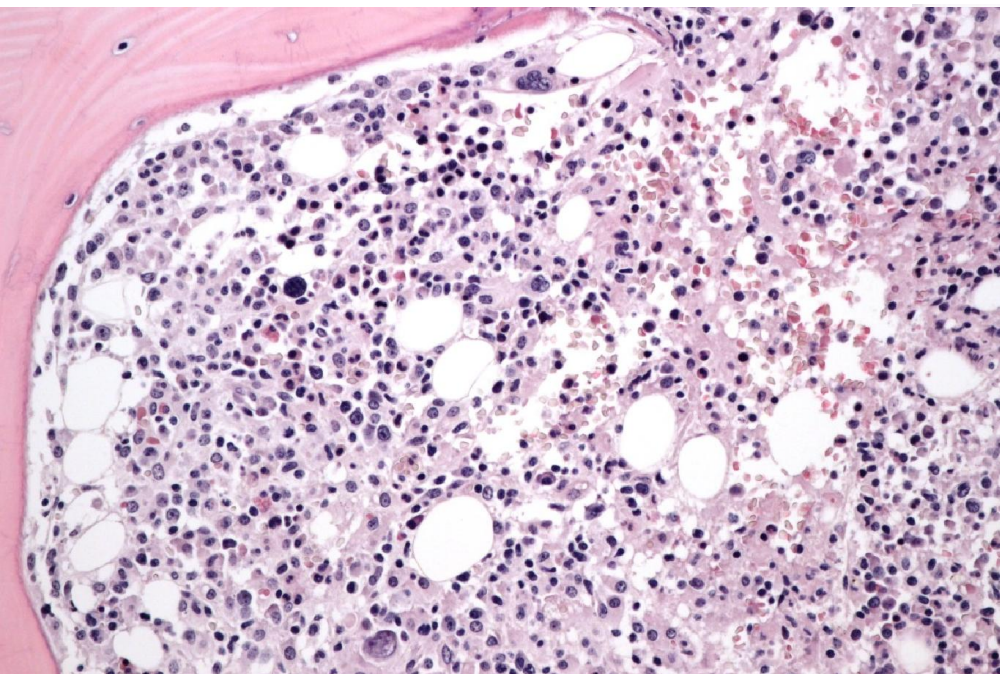
- 白细胞数正常。
- 粒细胞比例正常，可见原幼粒细胞
- 成熟红细胞形态未见明显异常。计数100个白细胞未见有核红细胞。
- 淋巴细胞比例减低，为成熟淋巴细胞。单核细胞比例增高，可见幼稚单核细胞。
- 血小板单个散在分布，少见。偶见大血小板。

诊断意见:
考虑CMML。





CD34



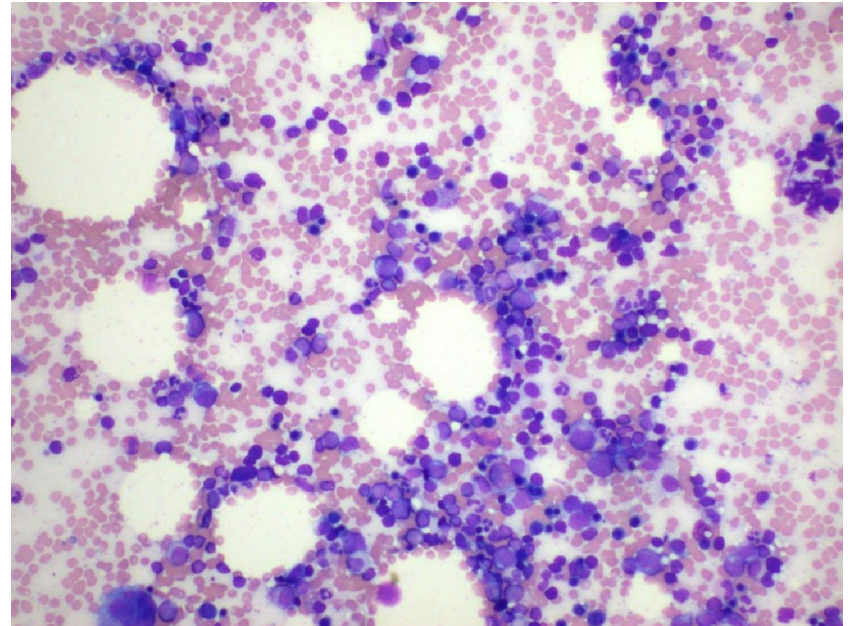
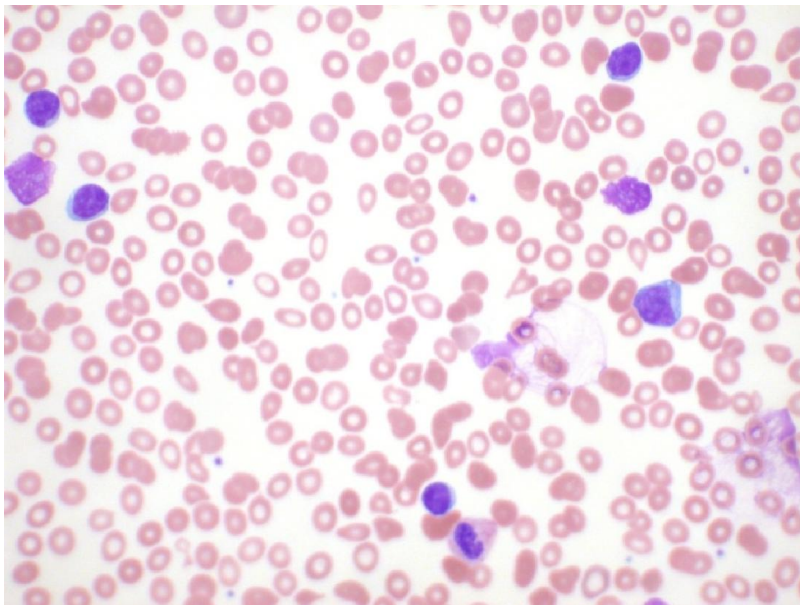
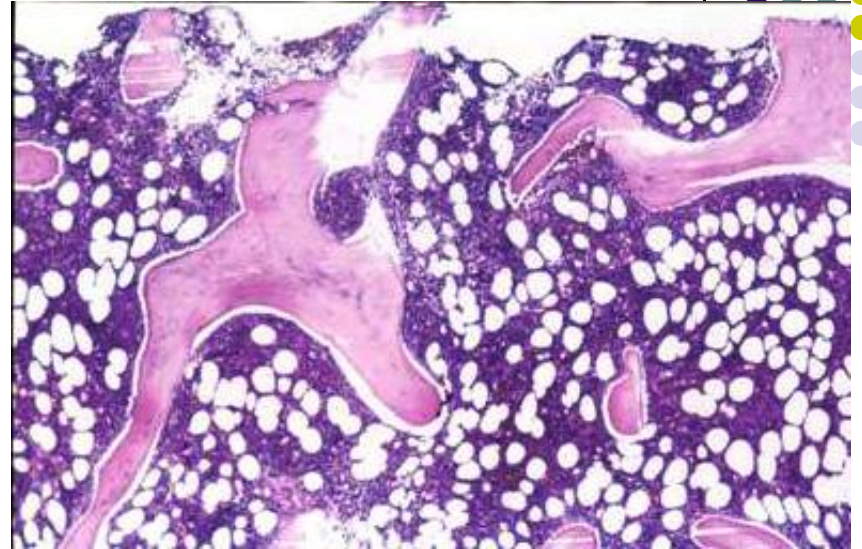


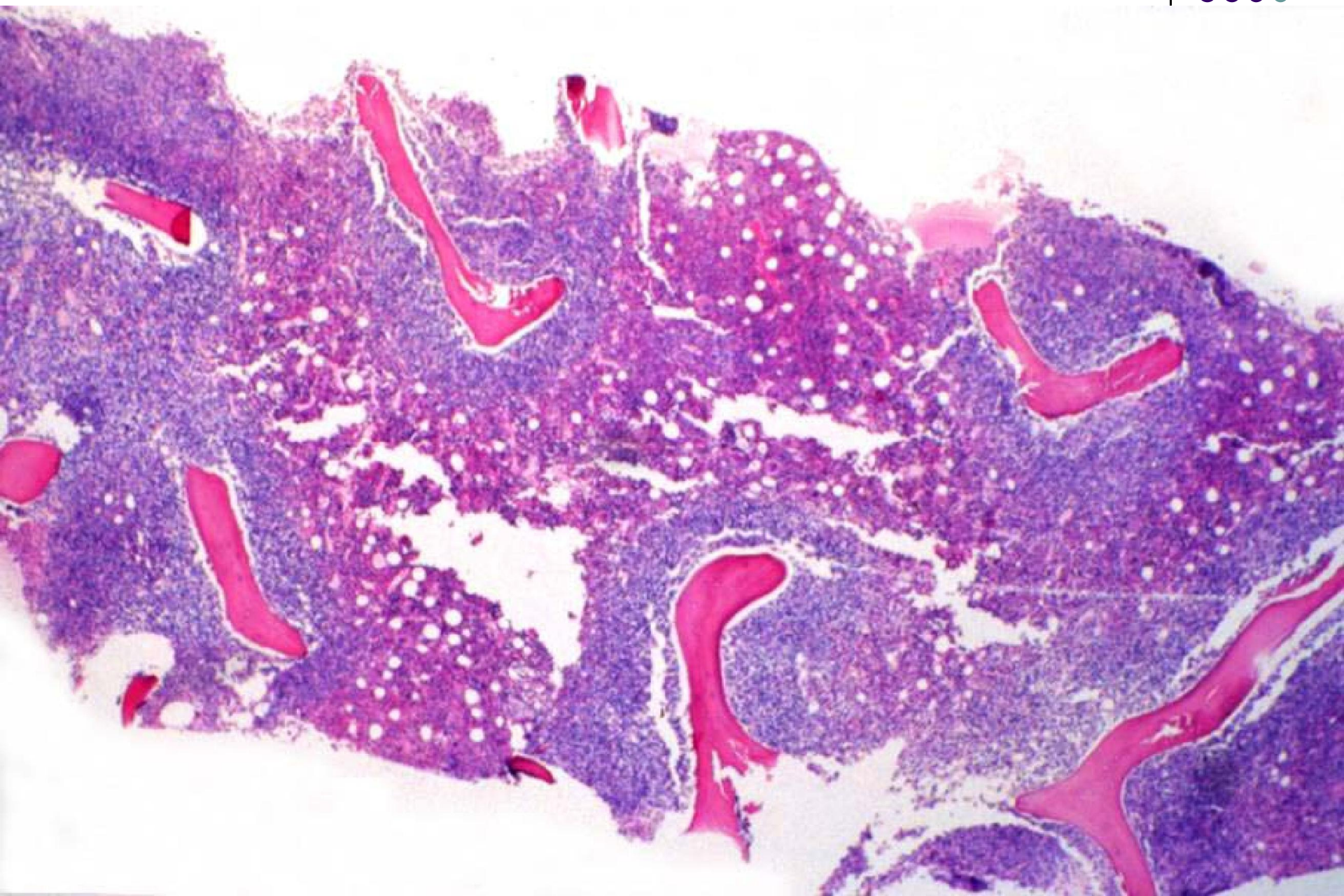
告诉你多少次了？ 病史！

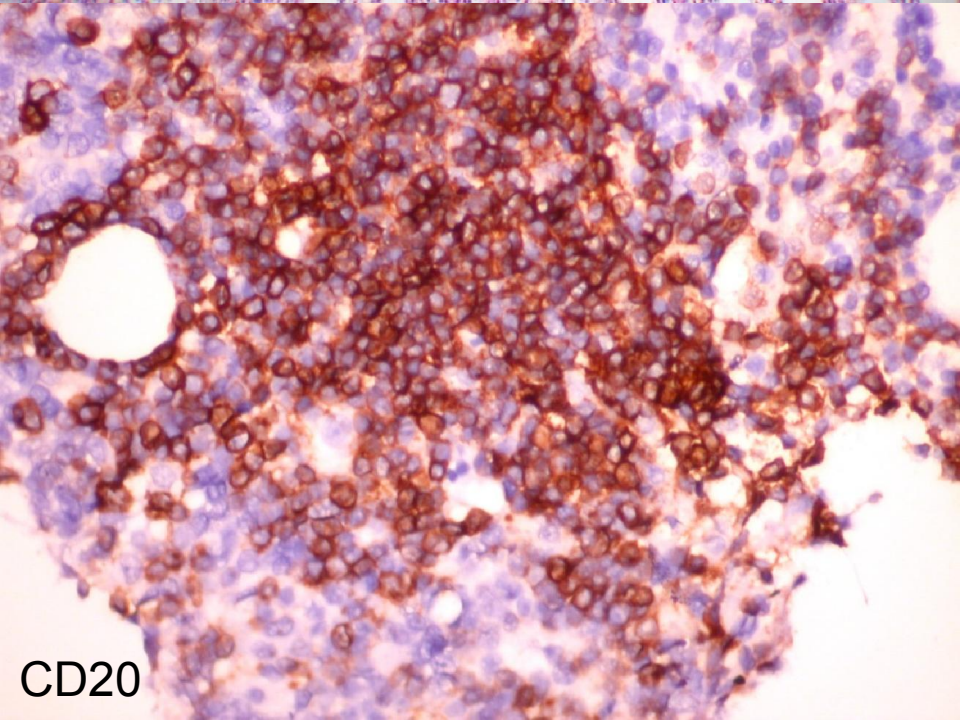
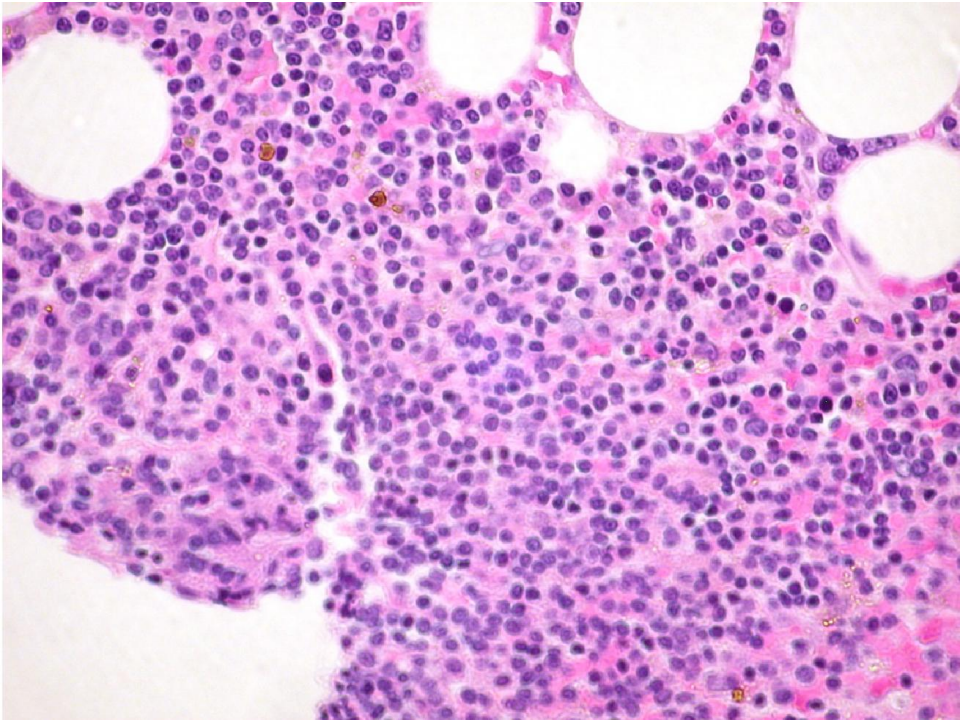
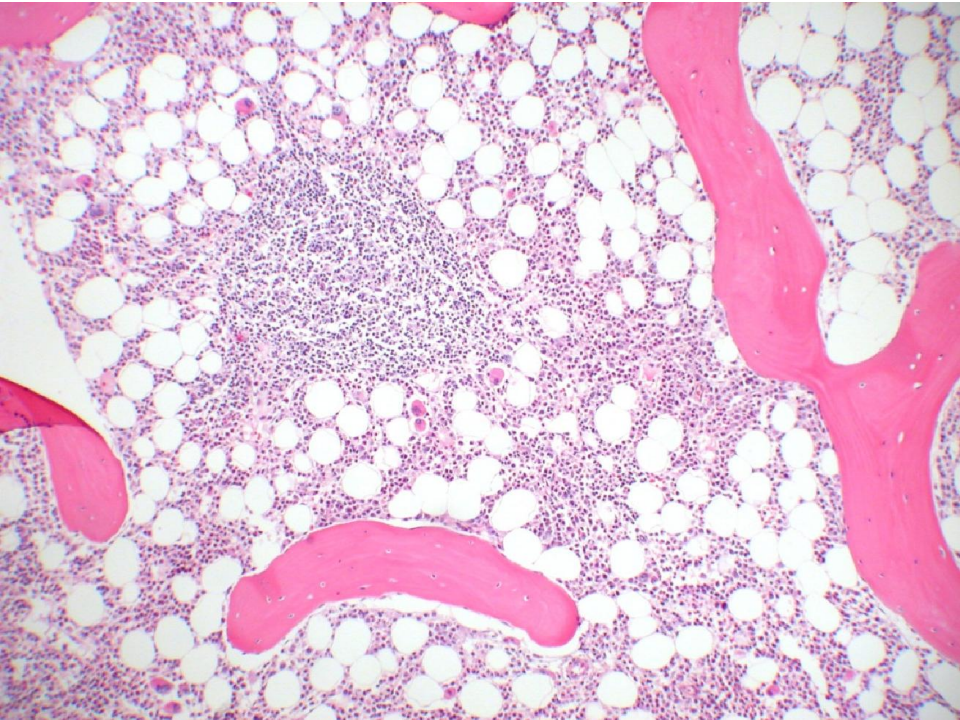
www.120.com.cn

形态学

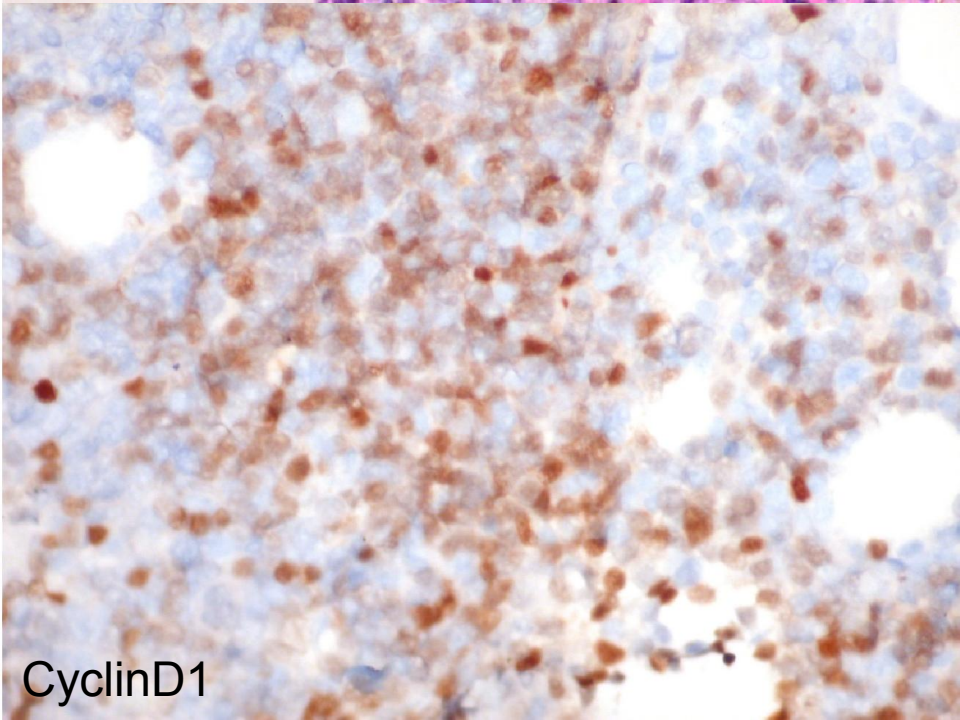
- 骨髓活检
- 骨髓涂片
- 外周血涂片



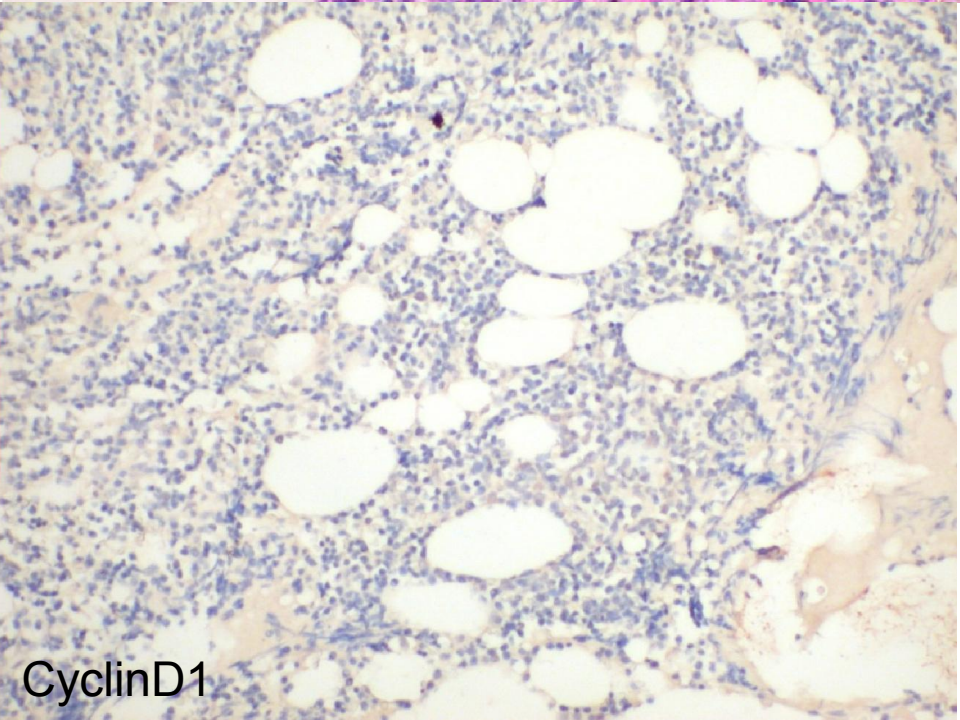
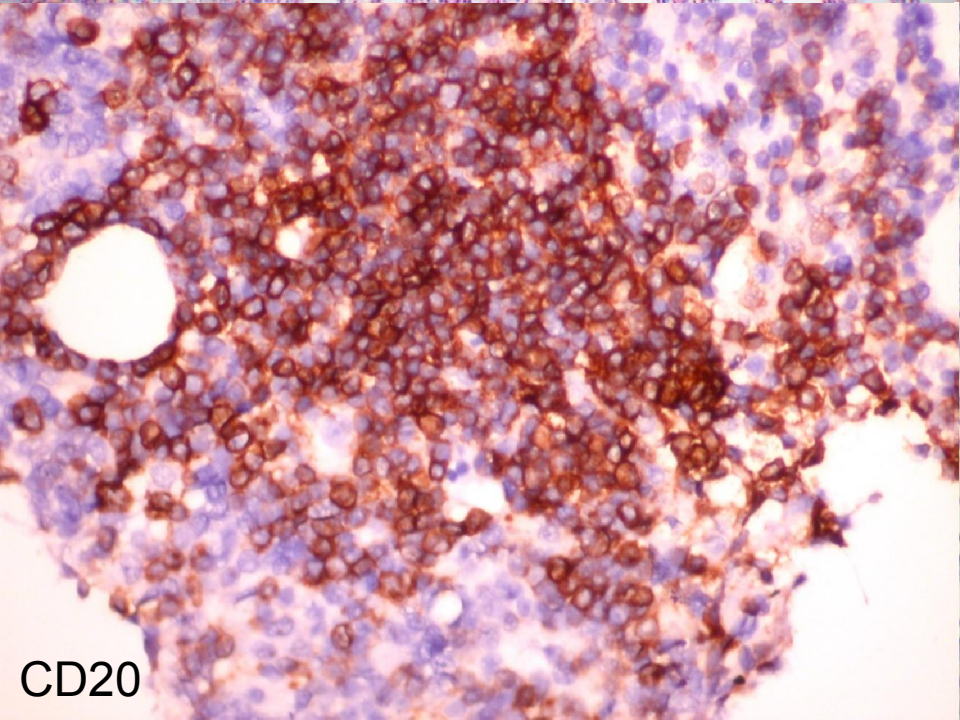
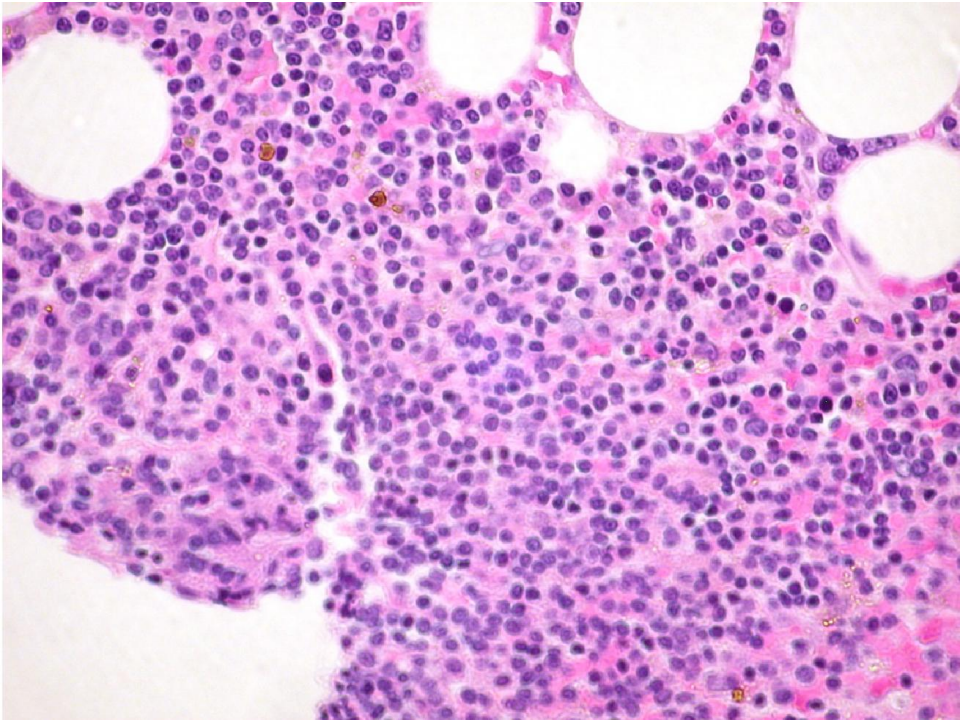
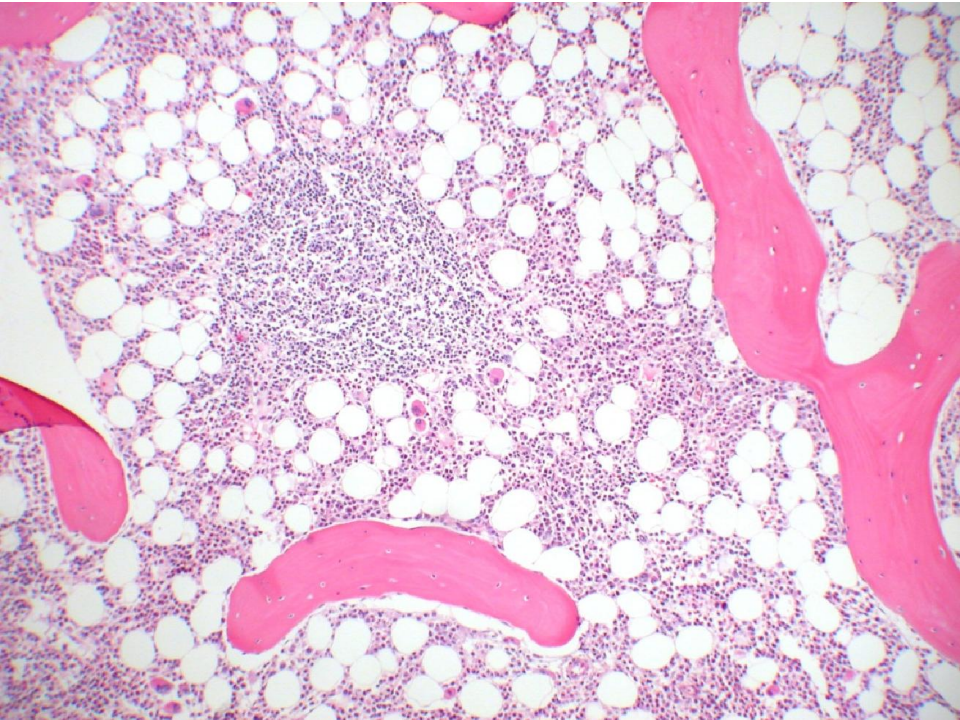




CD20

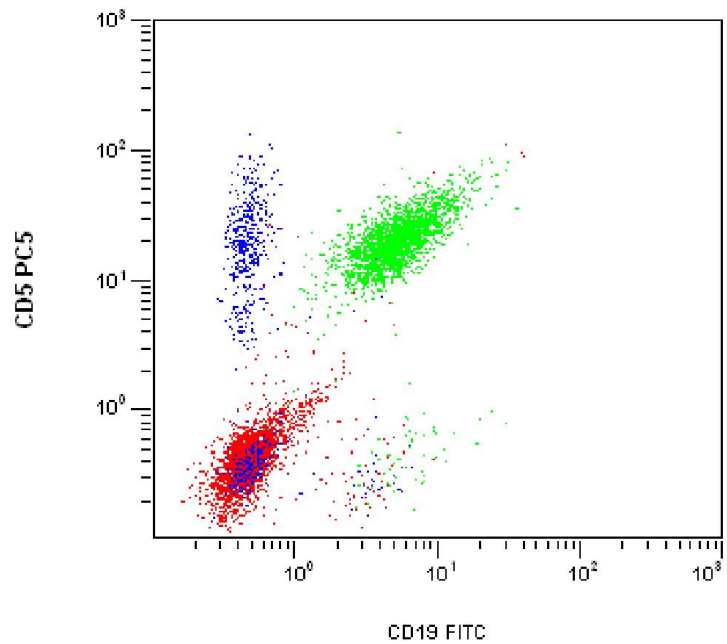


CyclinD1

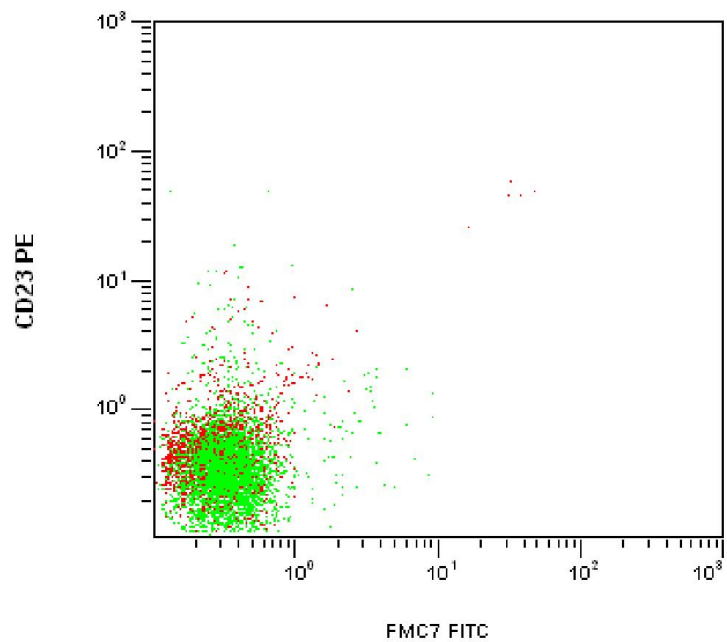


CD20

CyclinD1


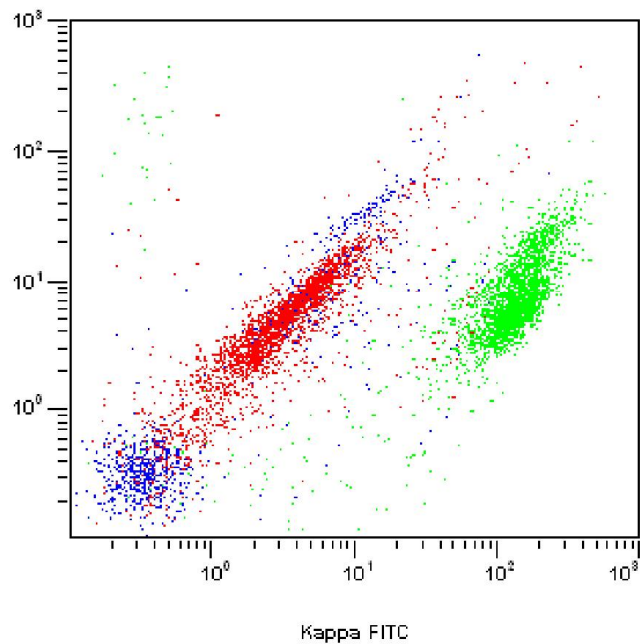



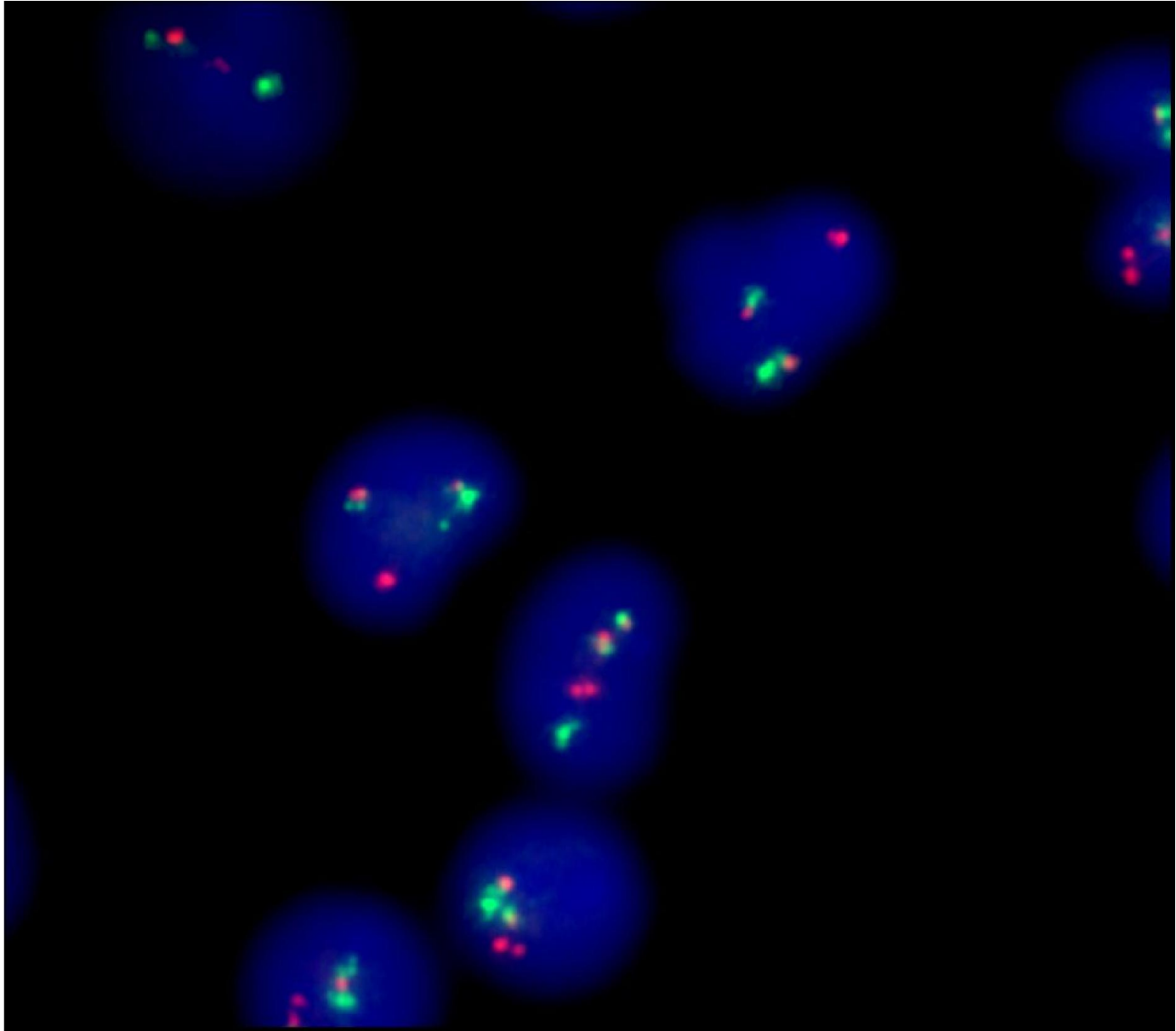
(F1)[A] qiu weihan 143 2014-04-03 053.LMD : FL1 Log/FL2 Log - ADC

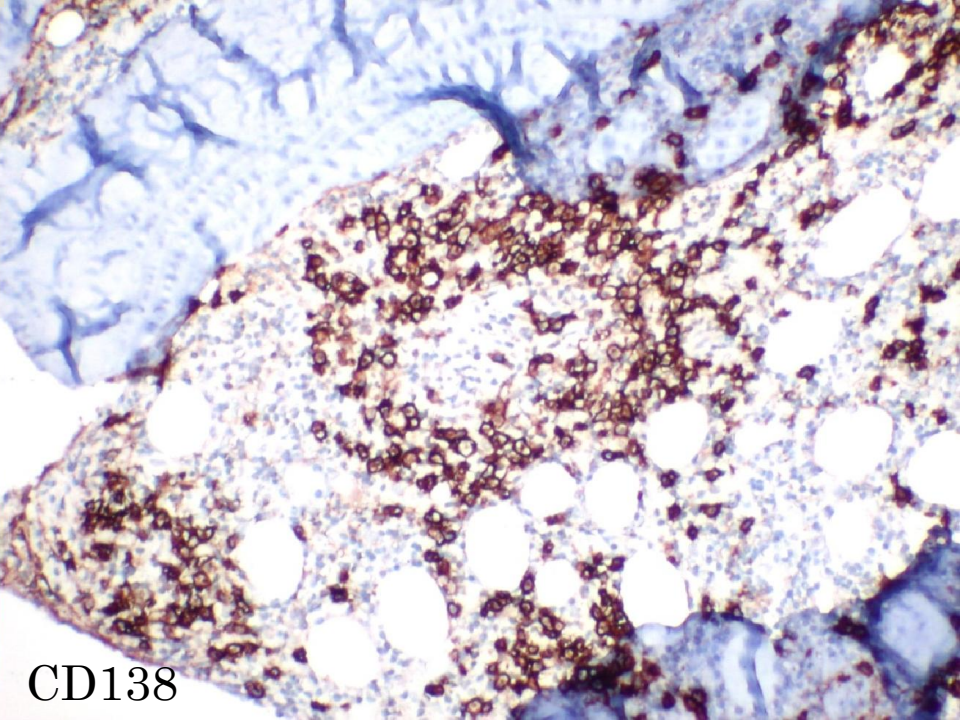
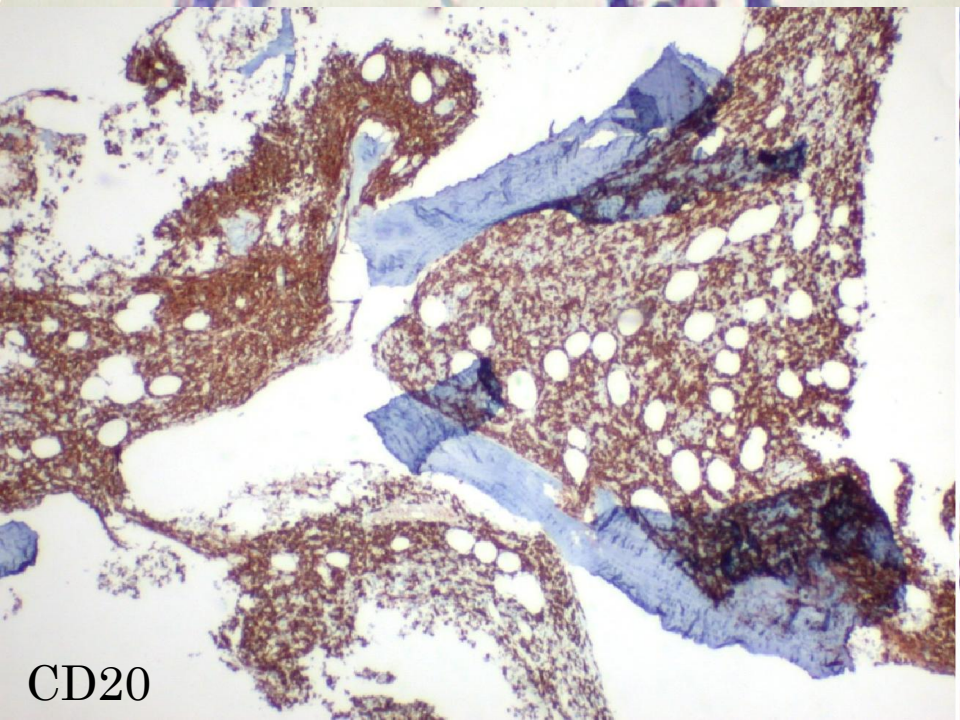
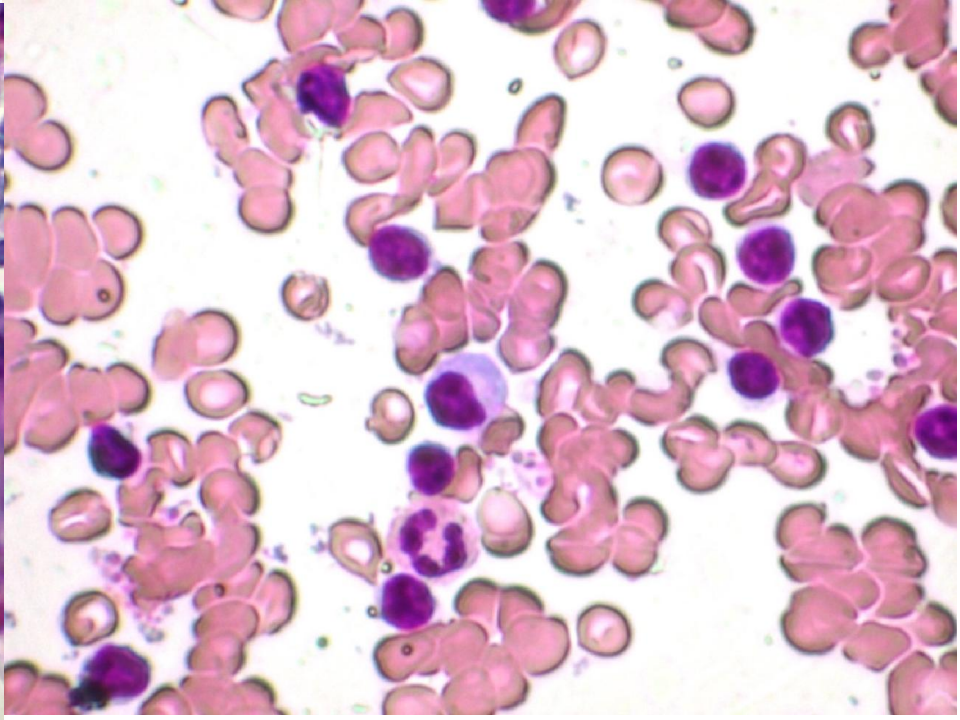
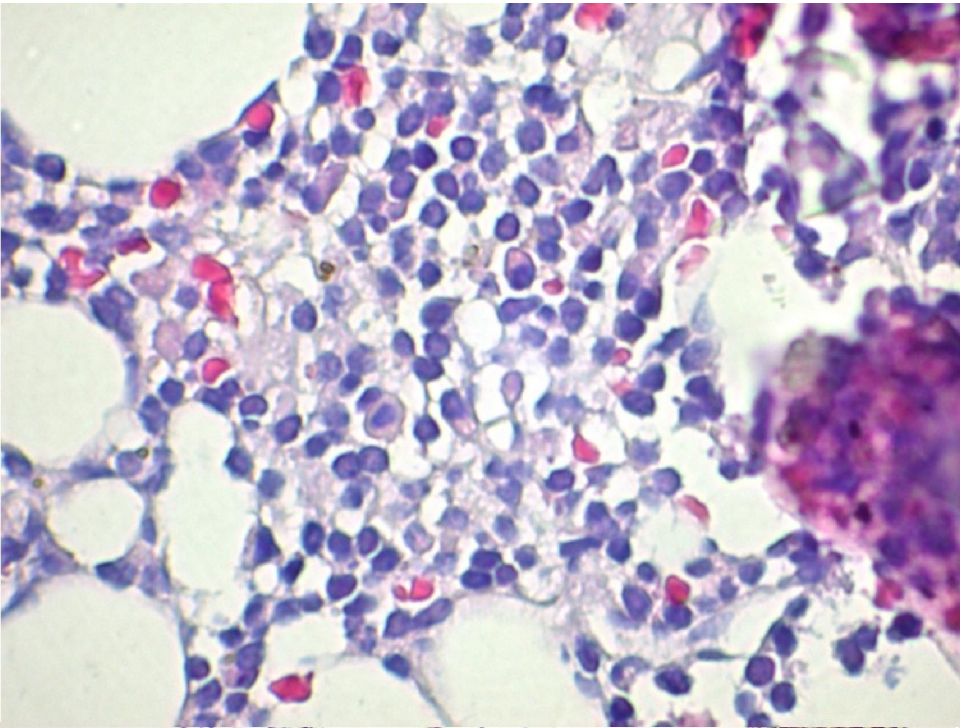


Lambda PE

(F1)[A] qiu weihan 143 2014-04-03 057.LMD : FL1 Log/FL2 Log - ADC







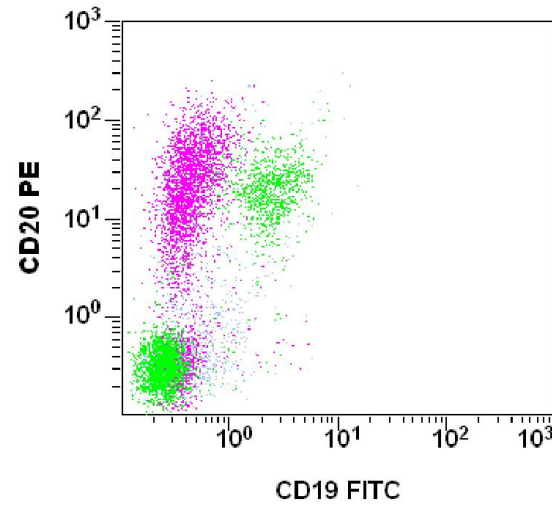
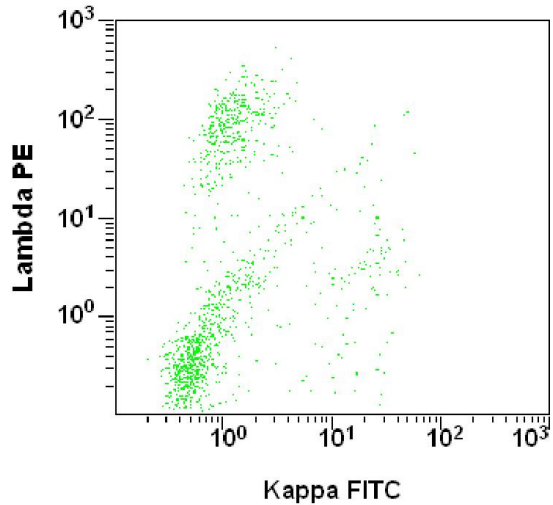
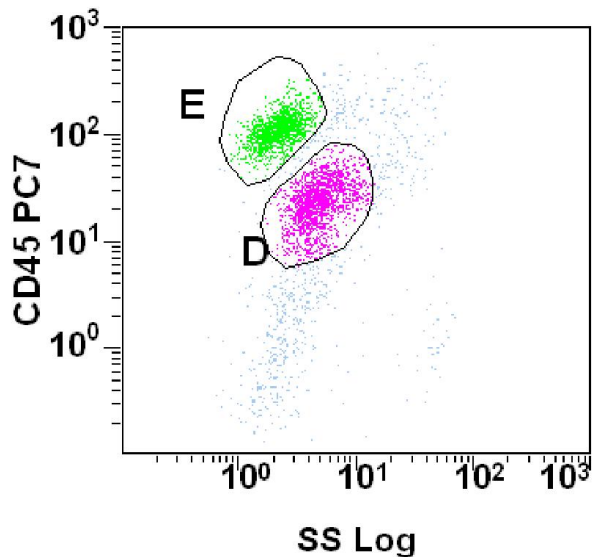
CD20

CD138

gfan 148 2013-12-18 191.LMD : SS Log/F

E] jia fenglan 148 2013-12-18 196.LMD : FL1 Log/FL

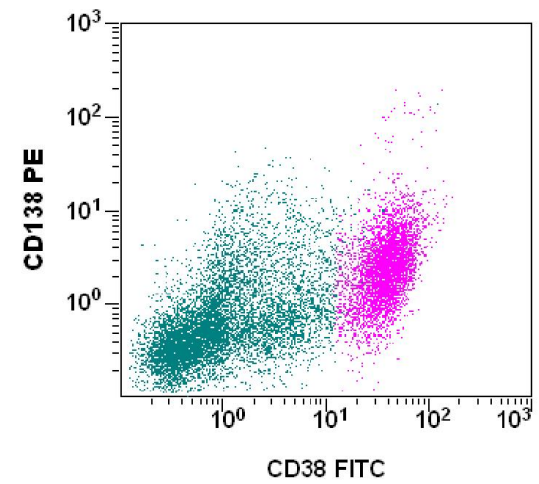
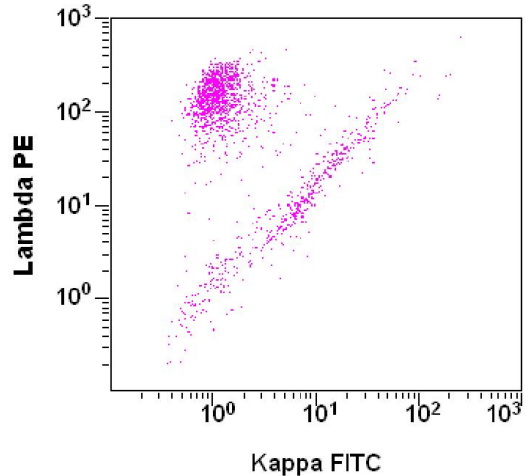
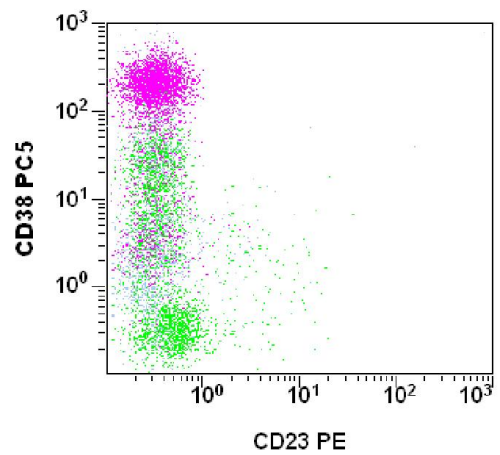
a fenglan 148 2013-12-18 191.LMD : FL1 Log/FL2 L

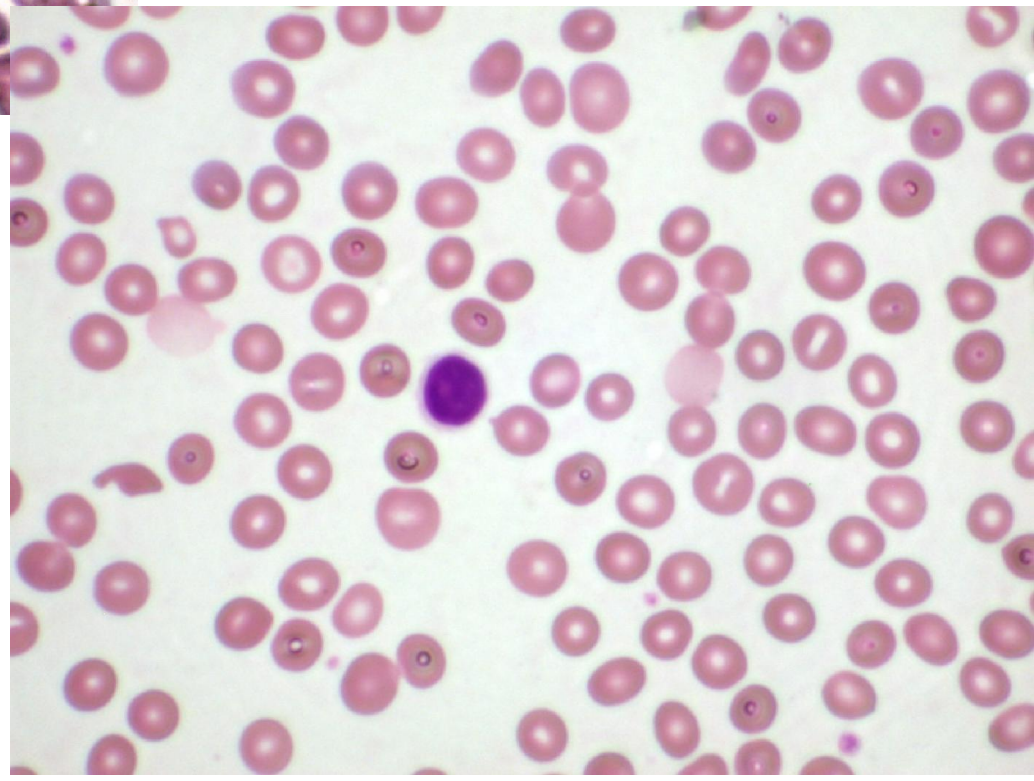

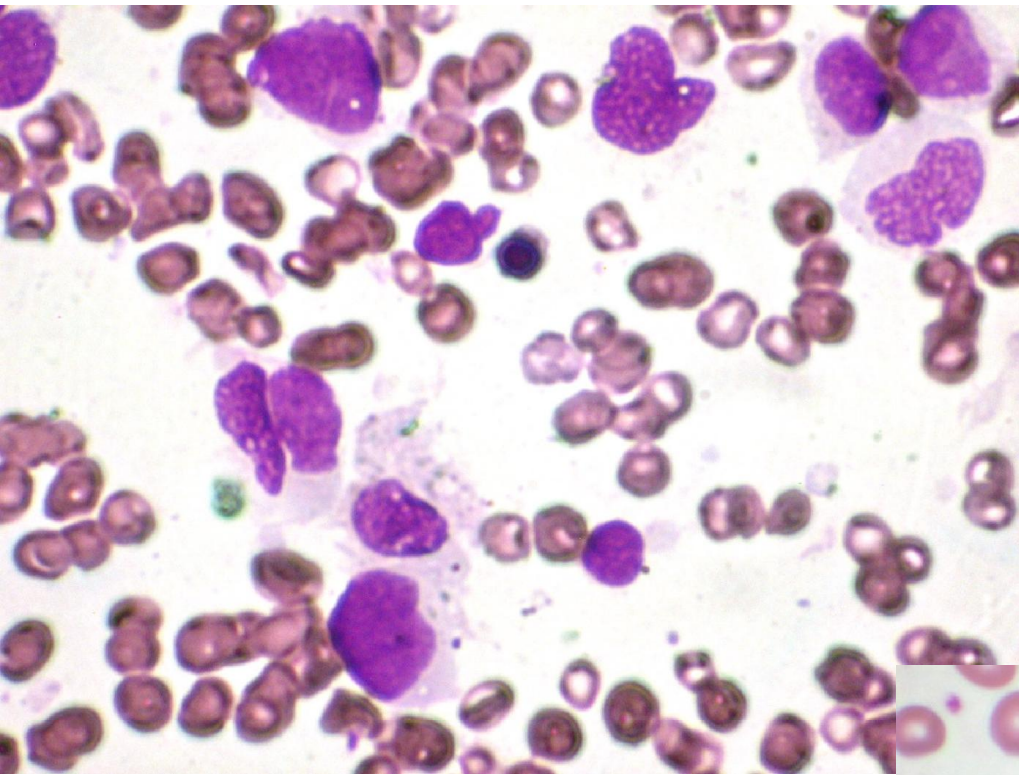


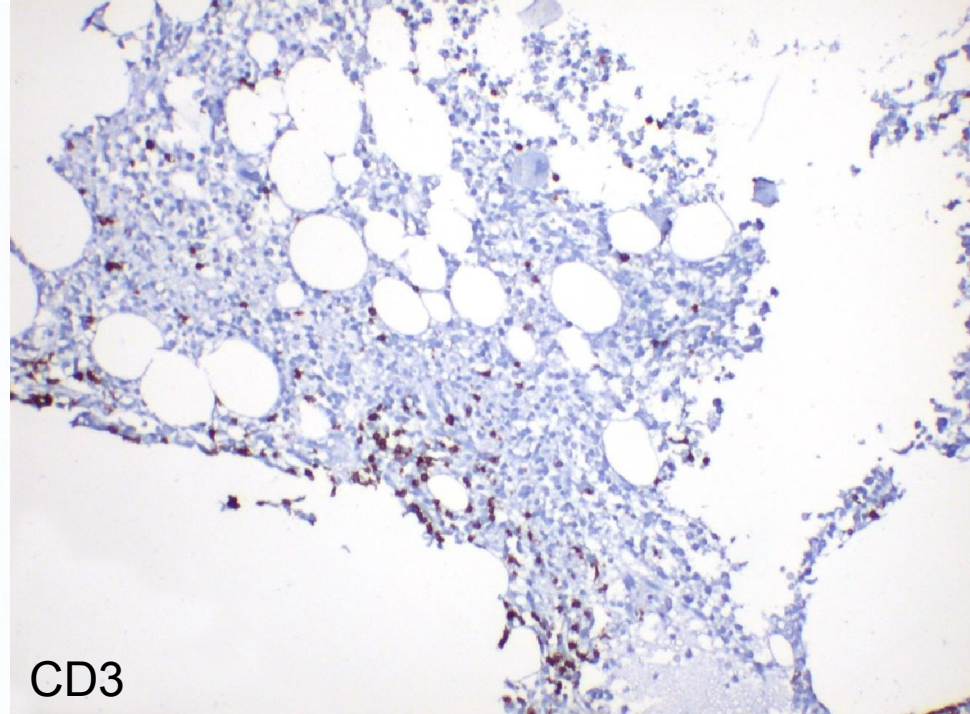
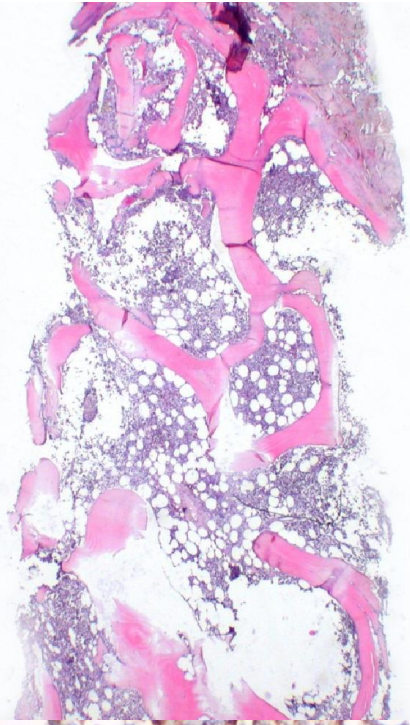
a fenglan 148 2013-12-18 192.LMD : FL2 Log/FL4 Lc

D] jia fenglan 148 2013-12-18 196.LMD : FL1 Log/FL

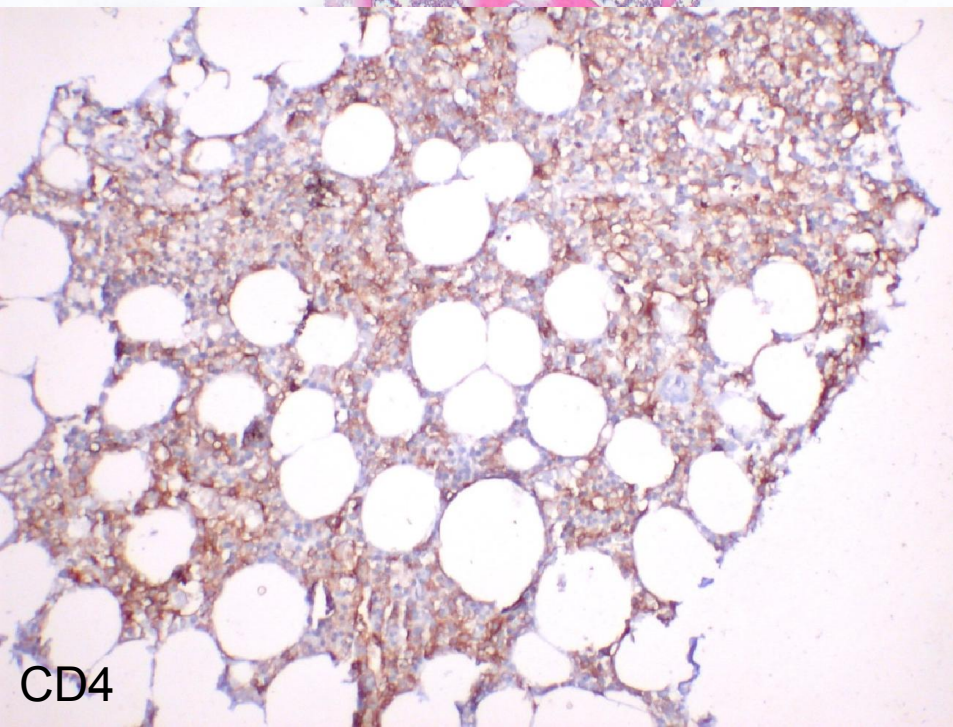
] jia fenglan 2013-12-18 352.LMD : FL1 Log/FL2 Log



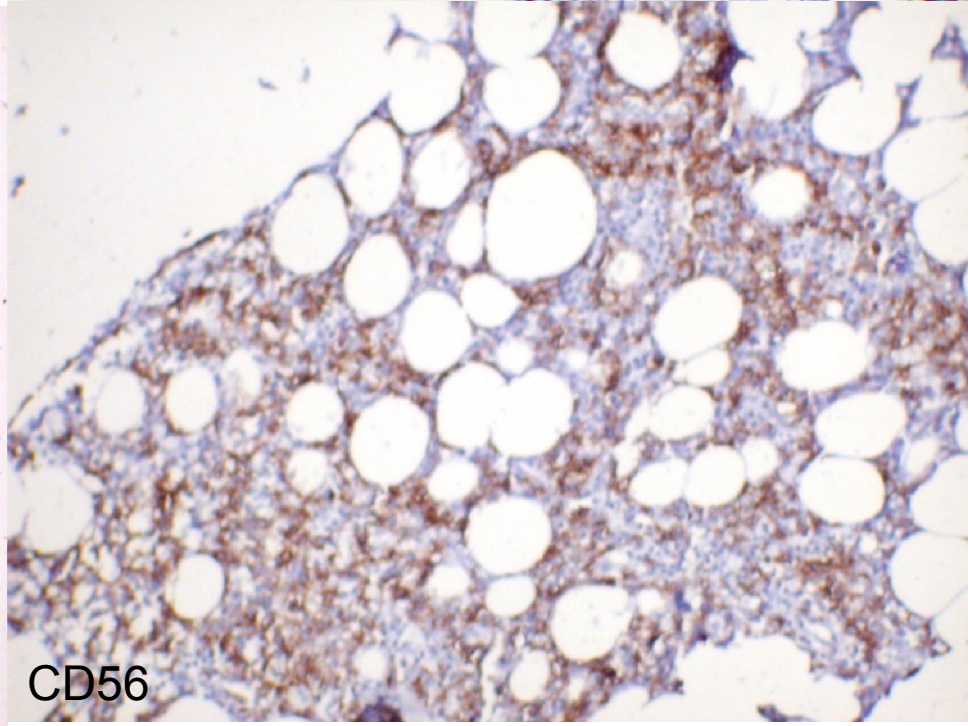




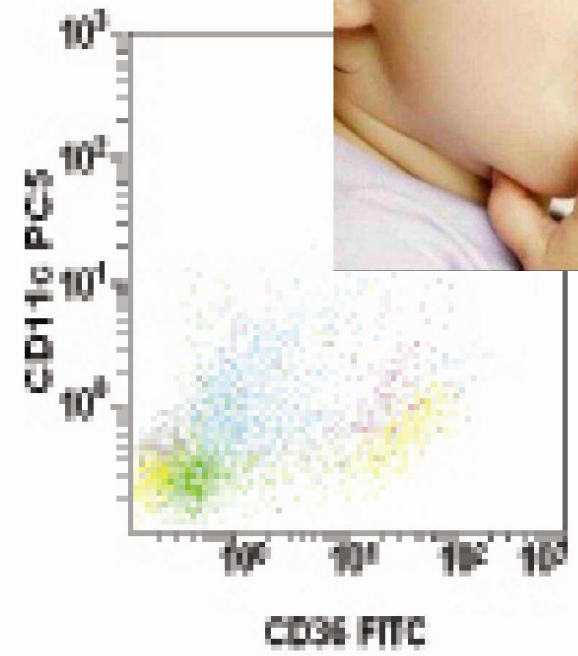
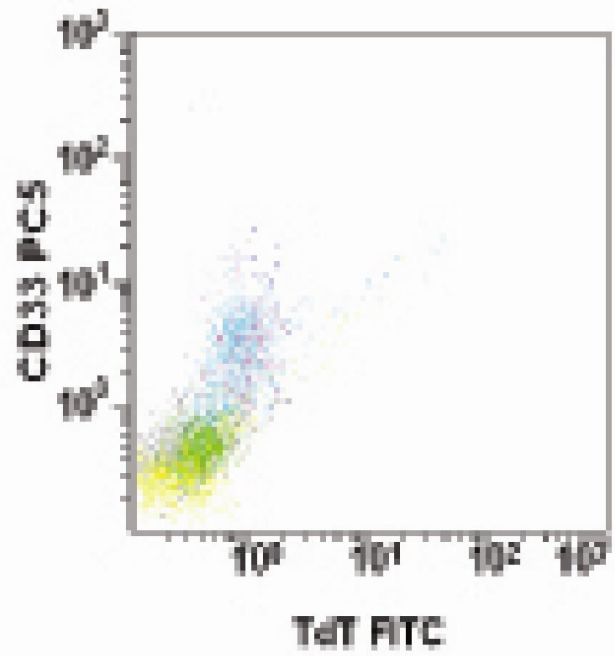
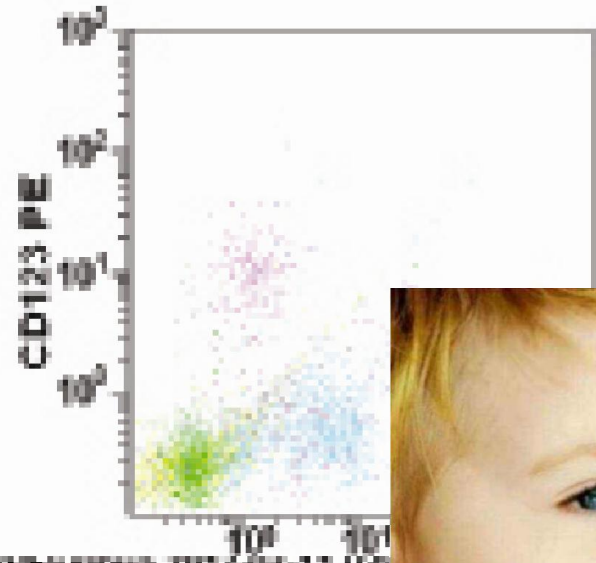
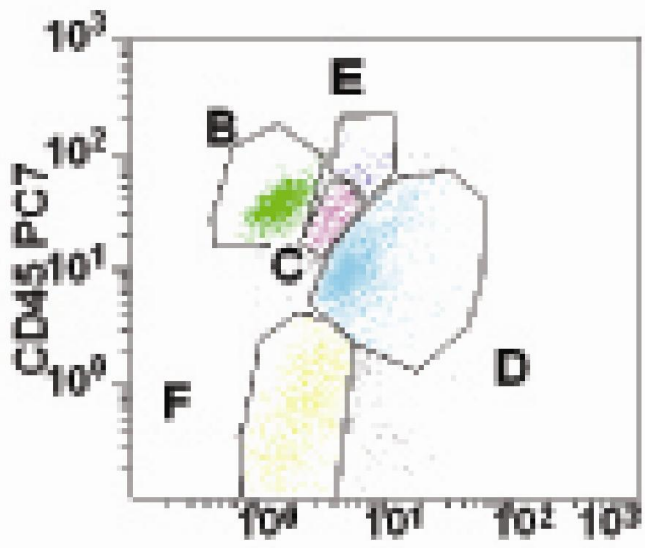

CD3

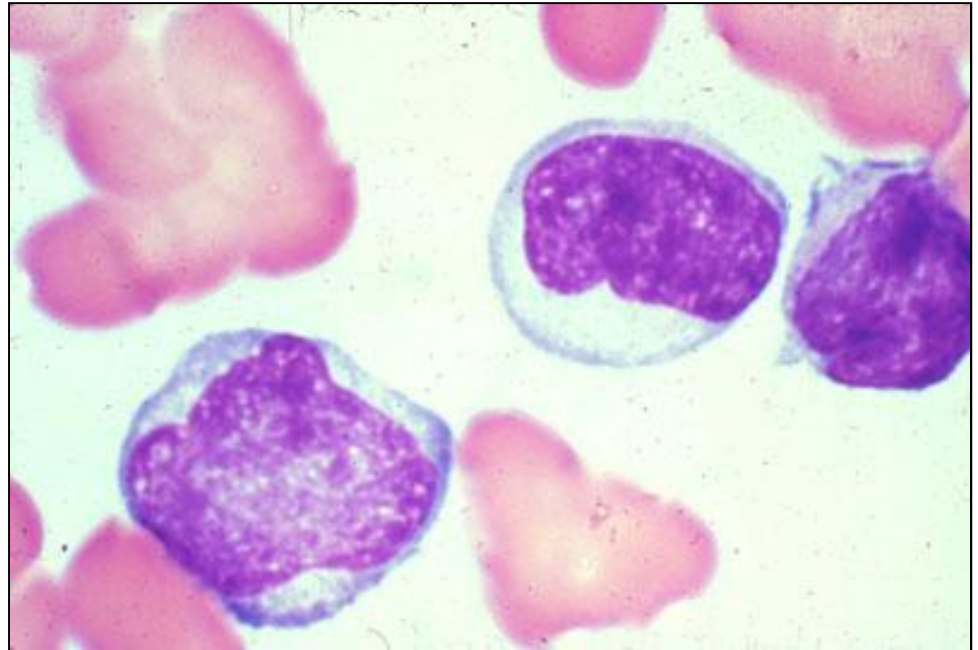
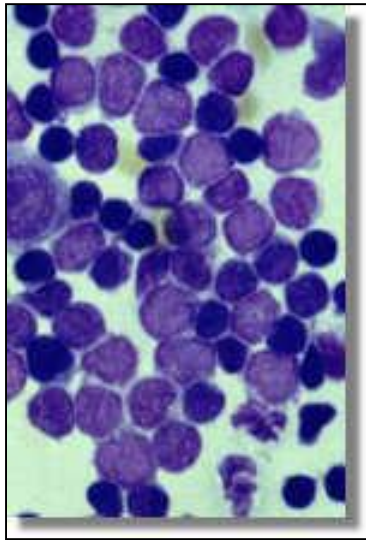
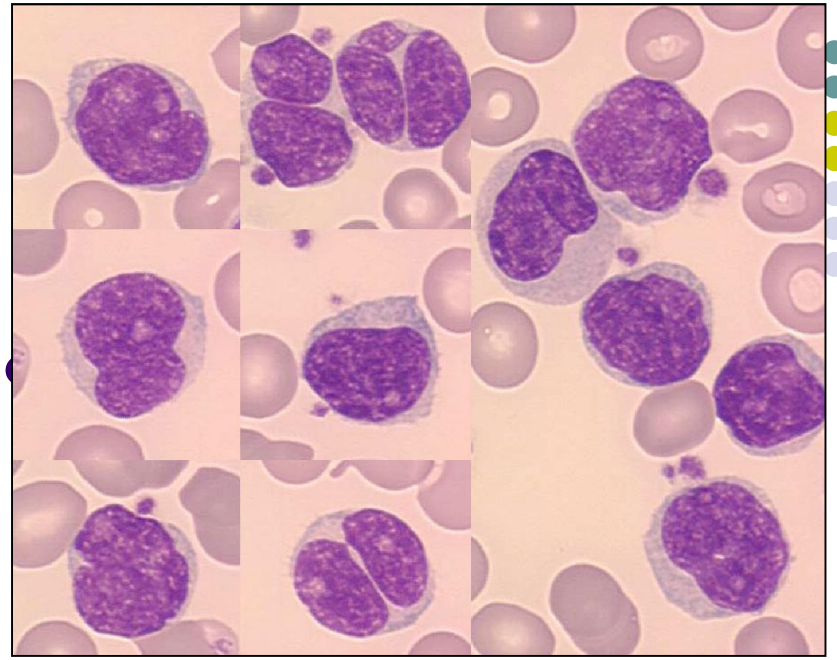
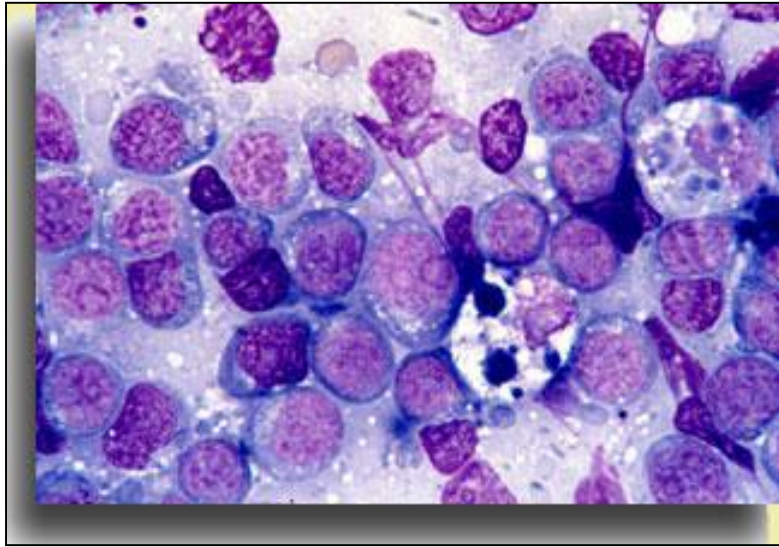


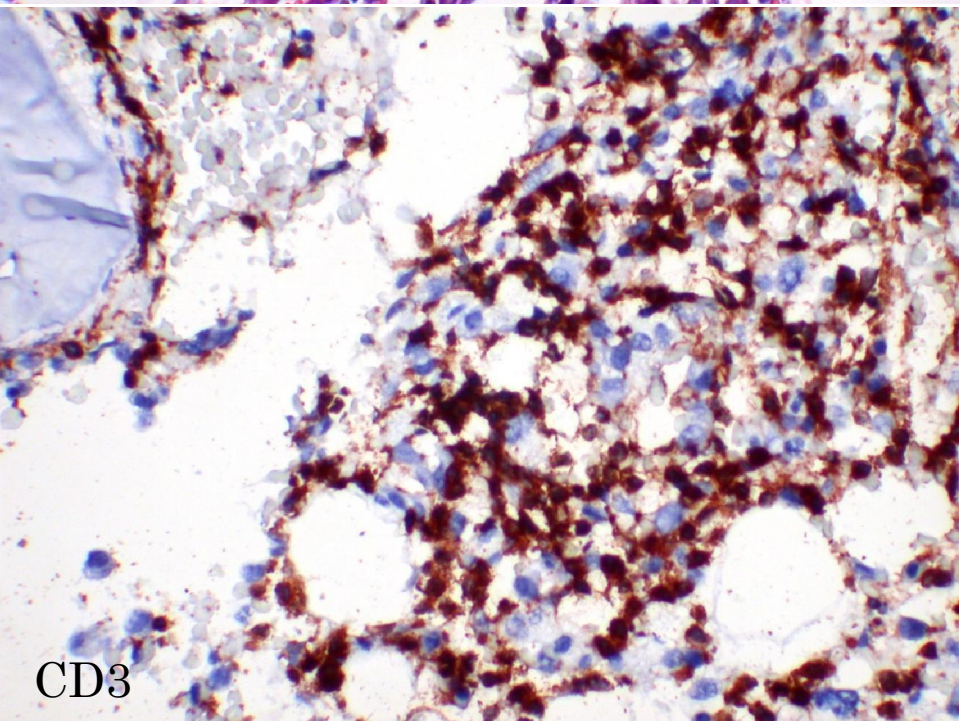
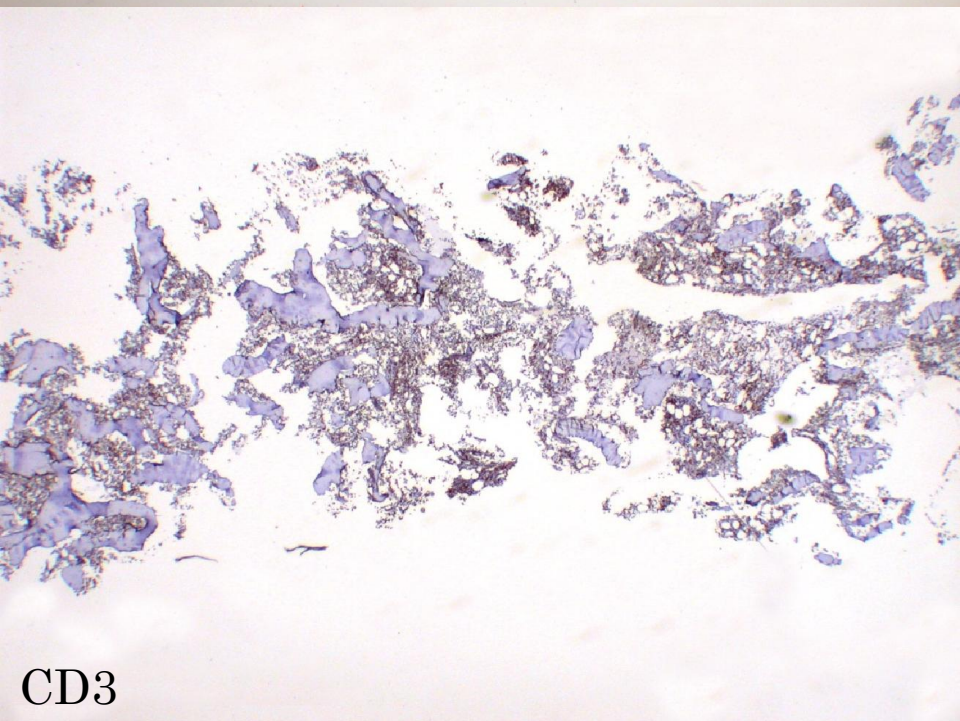
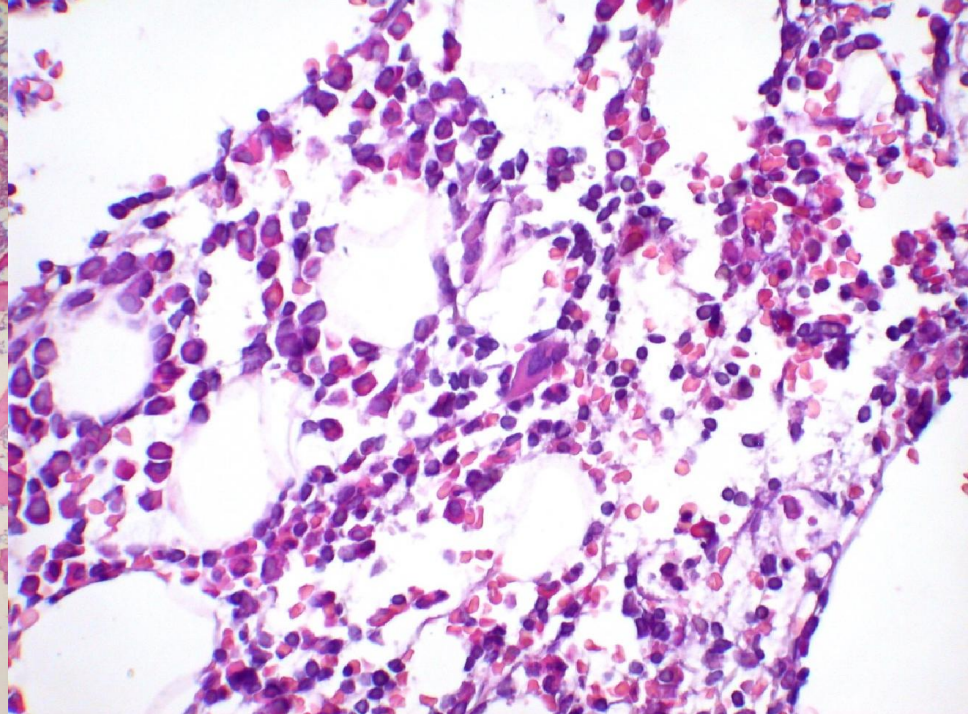
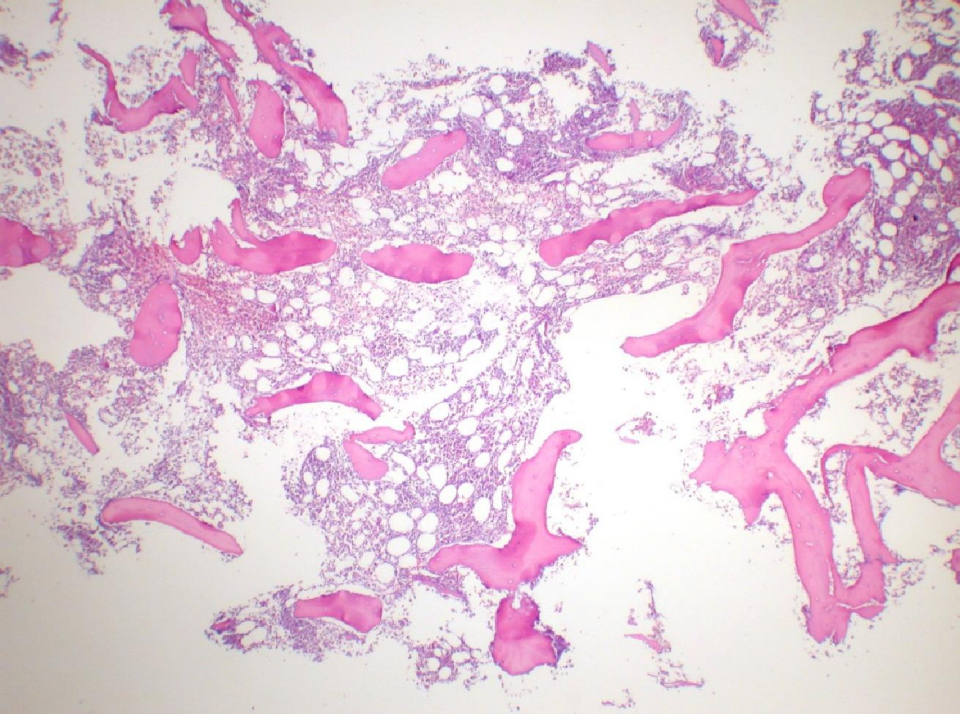
CD4



CD56

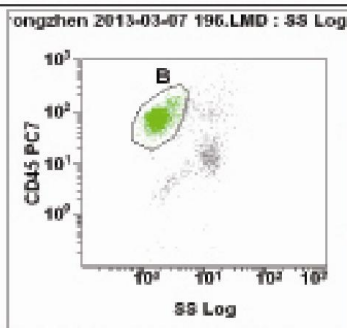





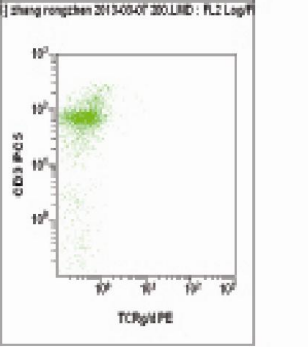
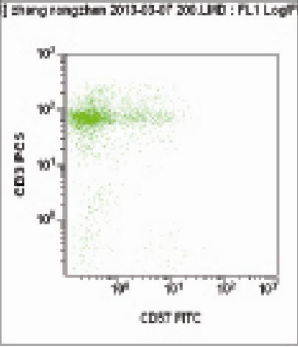
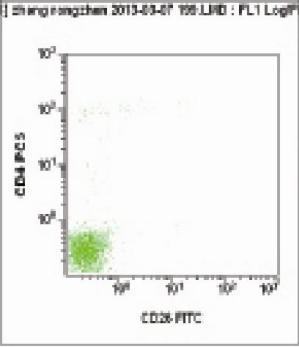
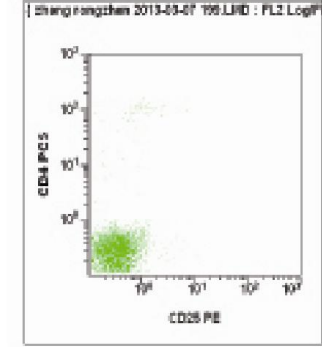
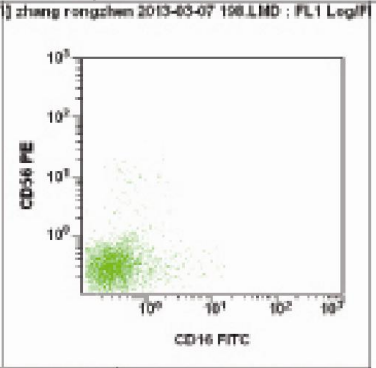
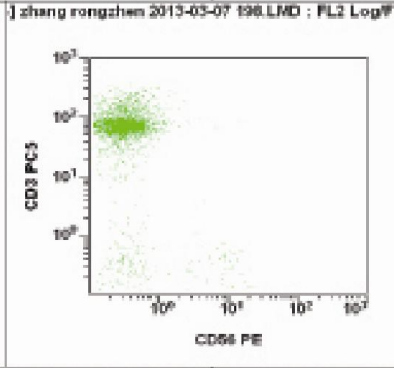
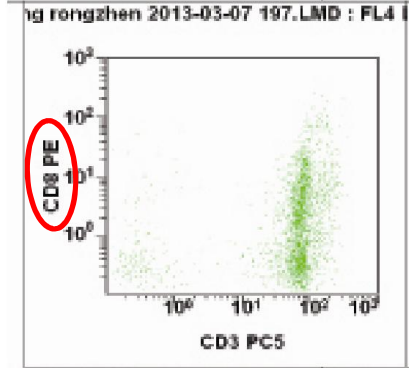
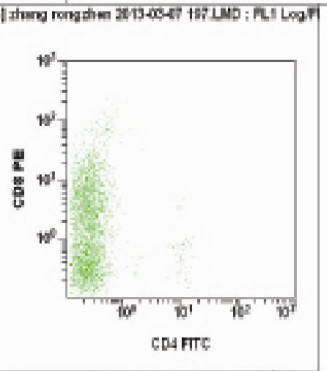
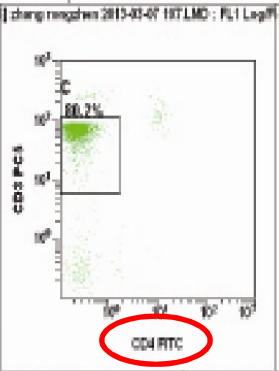
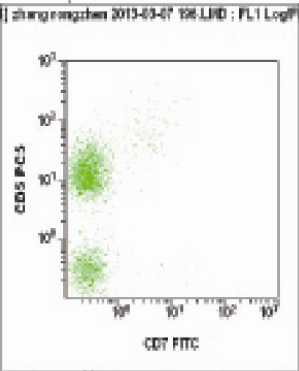
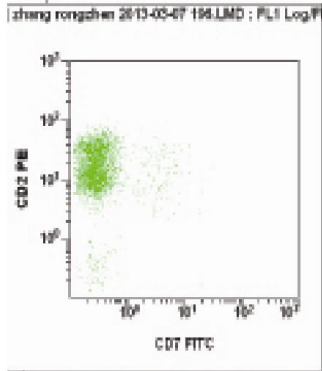
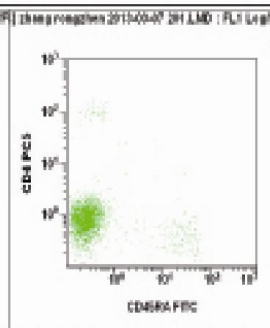
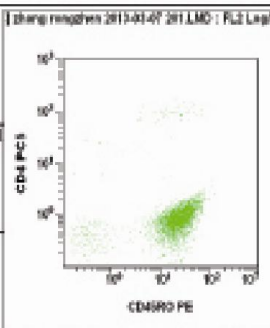


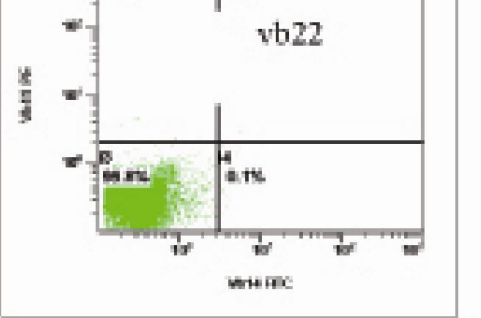
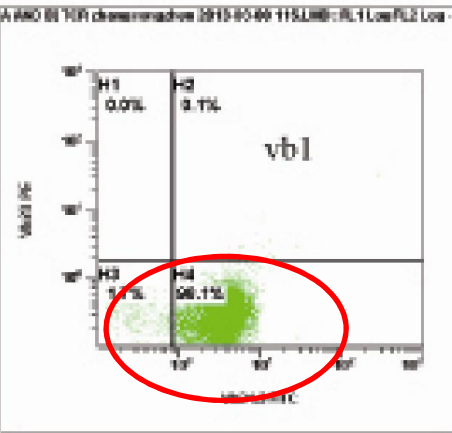
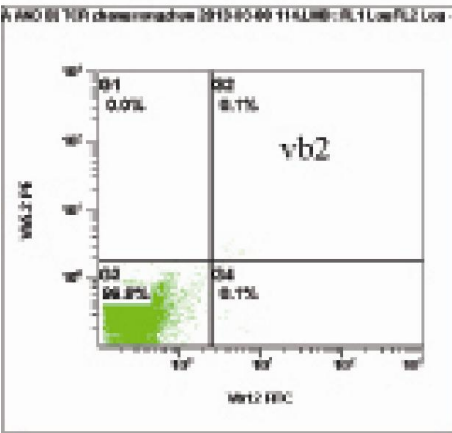
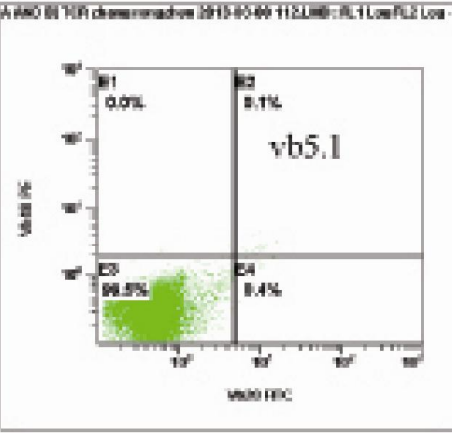
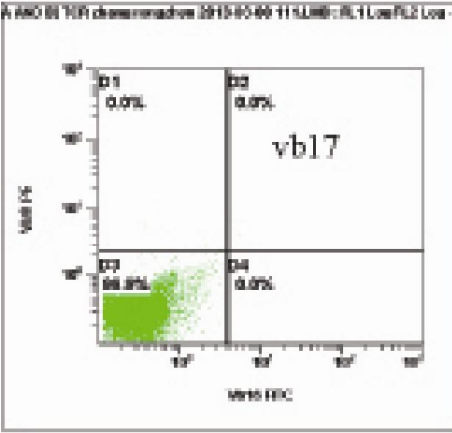
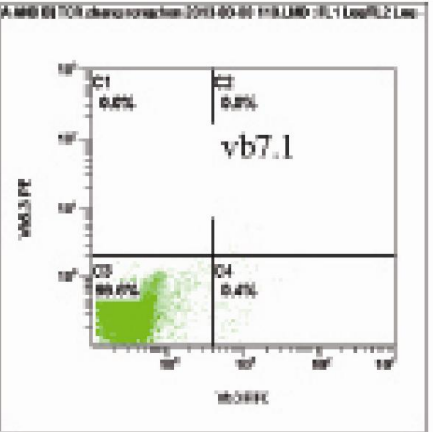
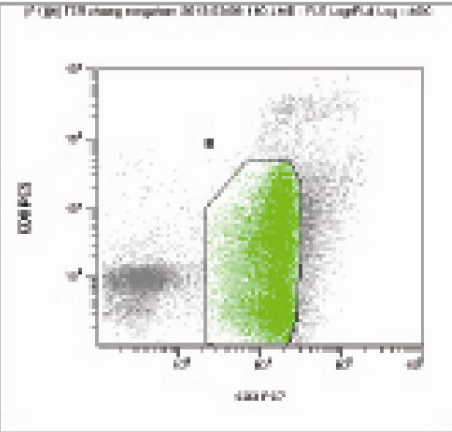
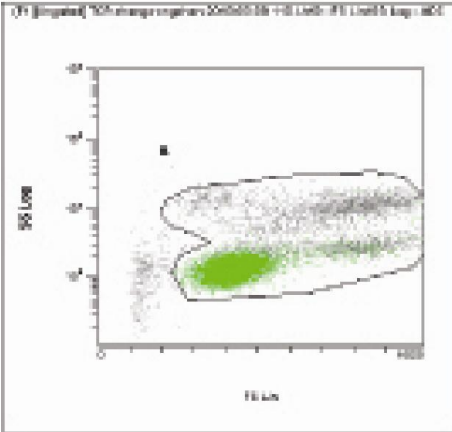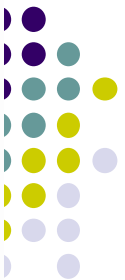
CD3

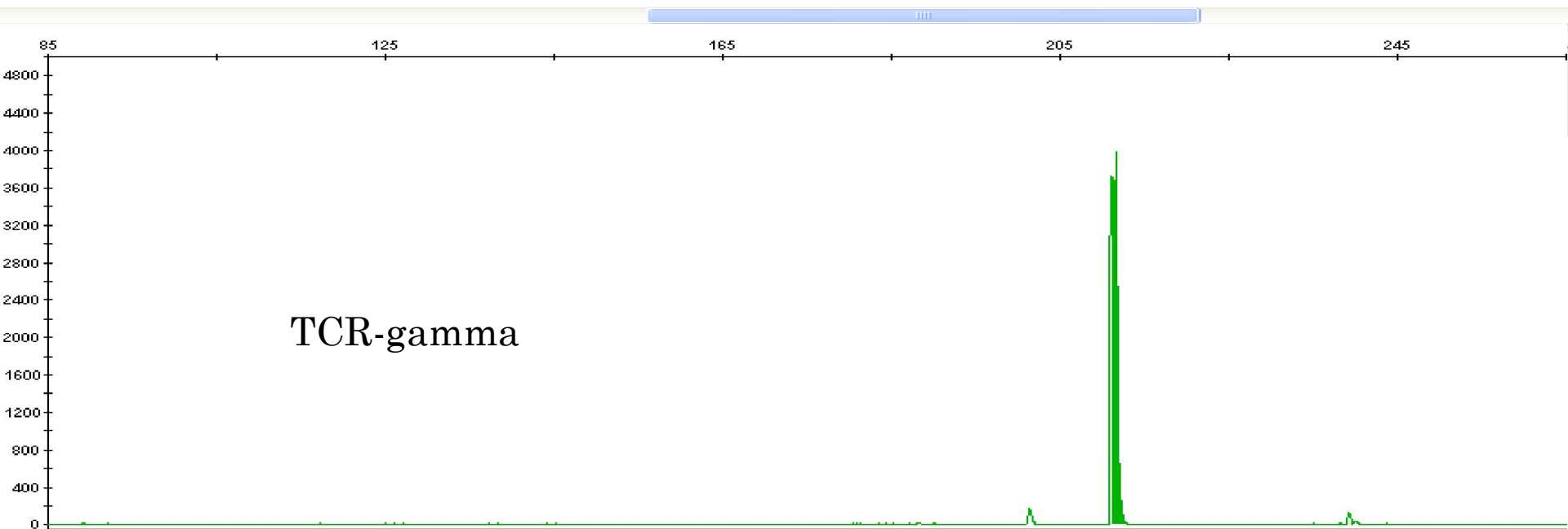
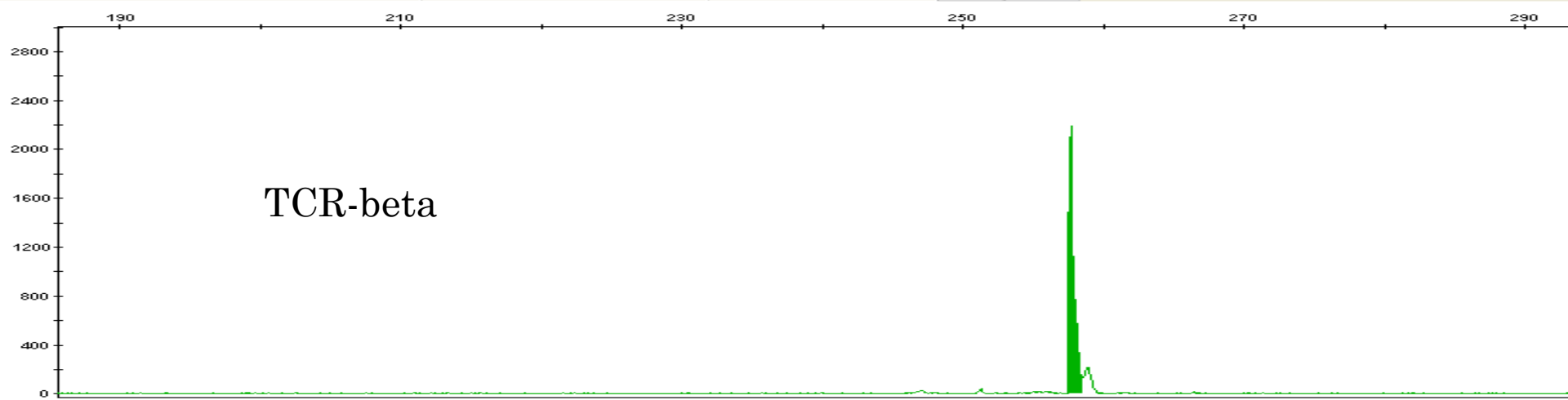
CD3



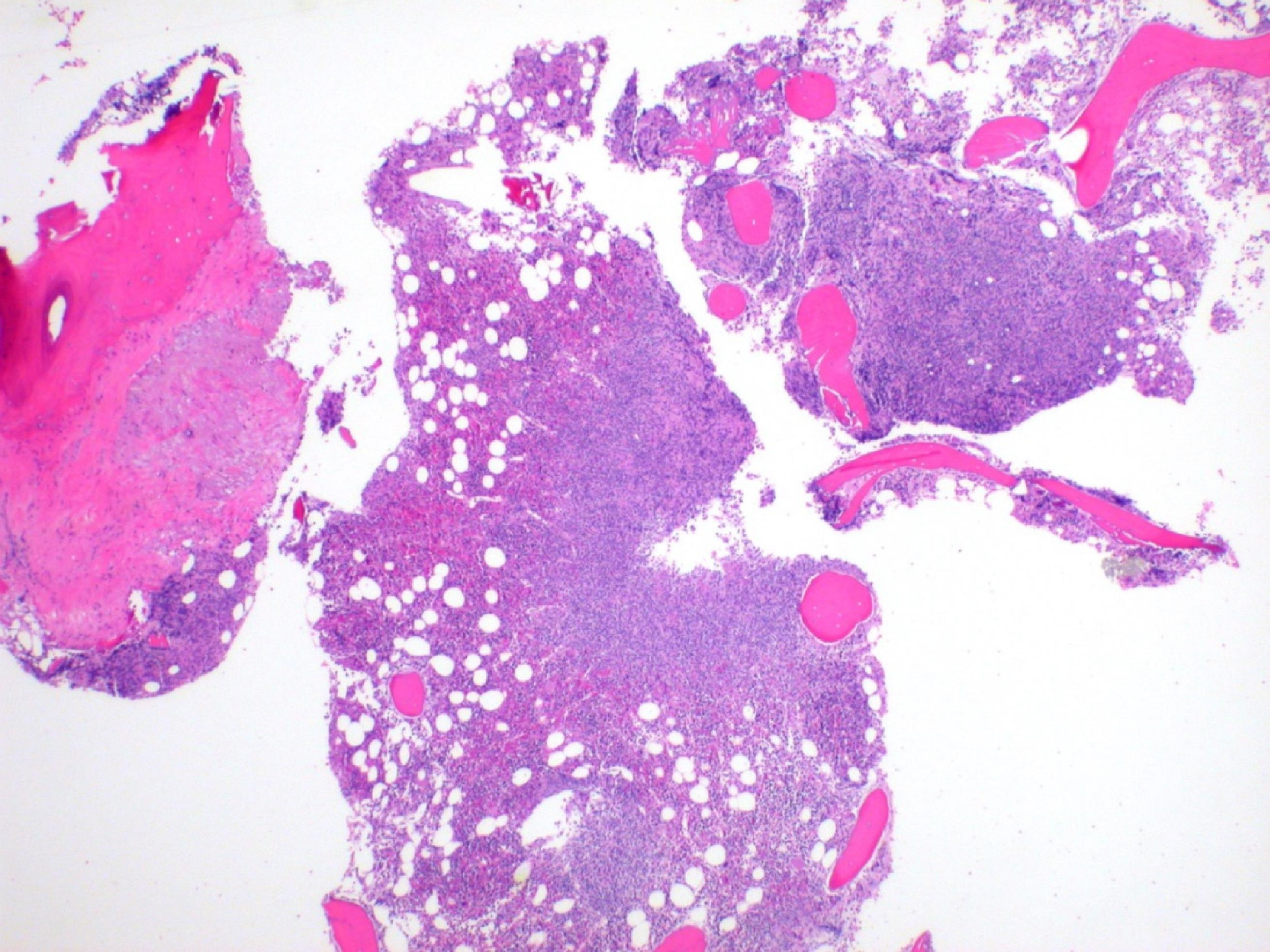
Region	Number	%Total	%Gated
ALL	9455	94.55	100.00
B	8025	80.25	84.88

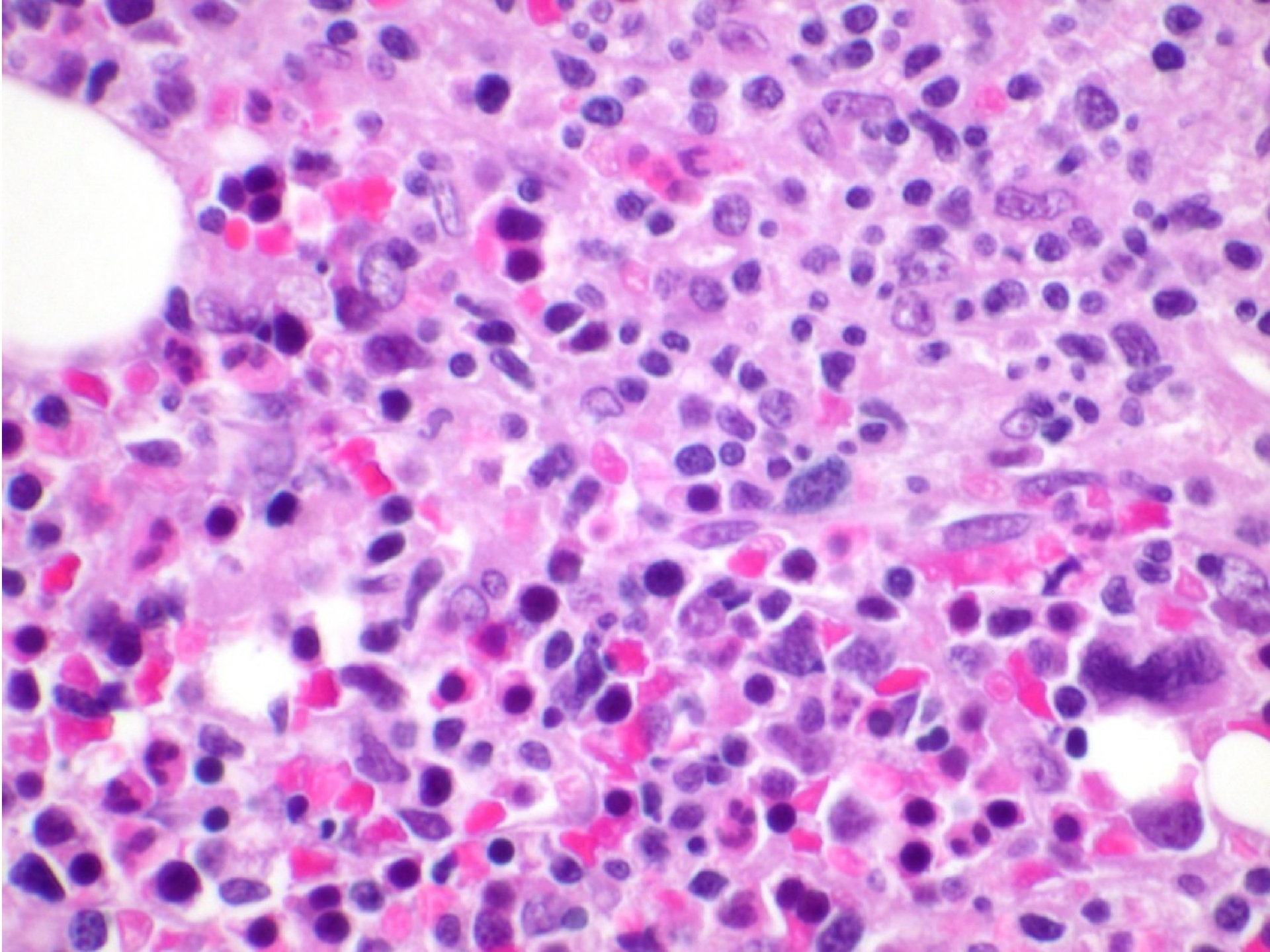






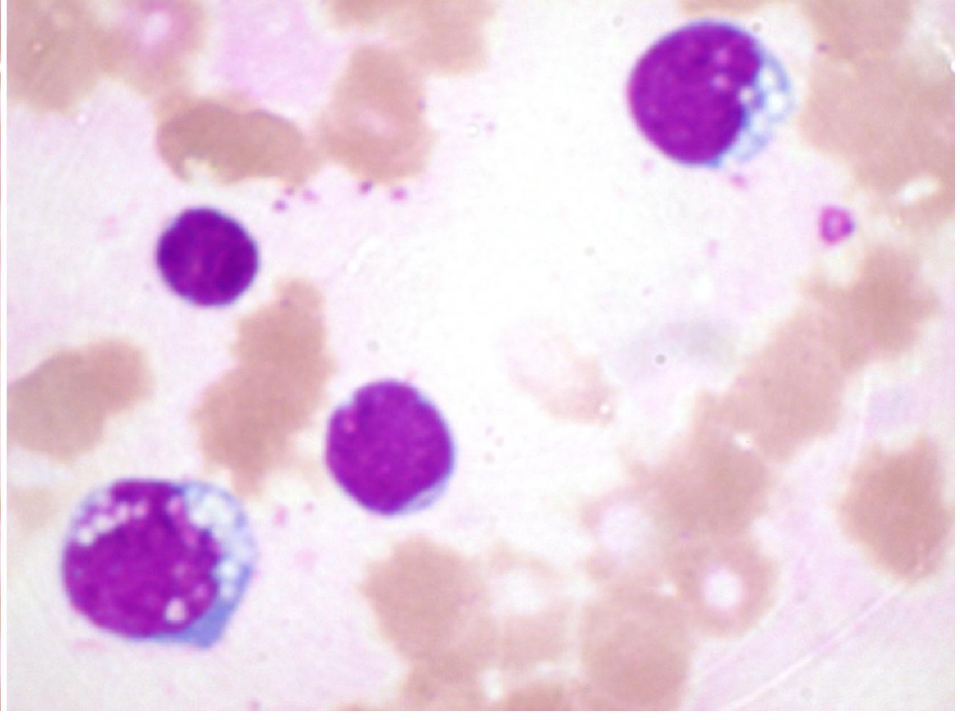
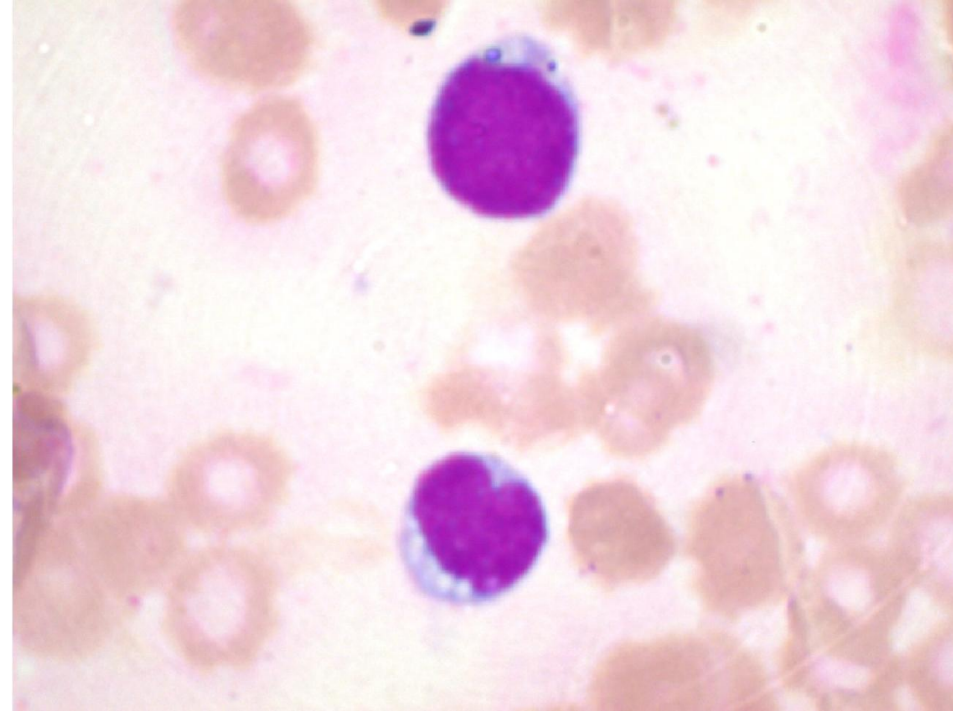
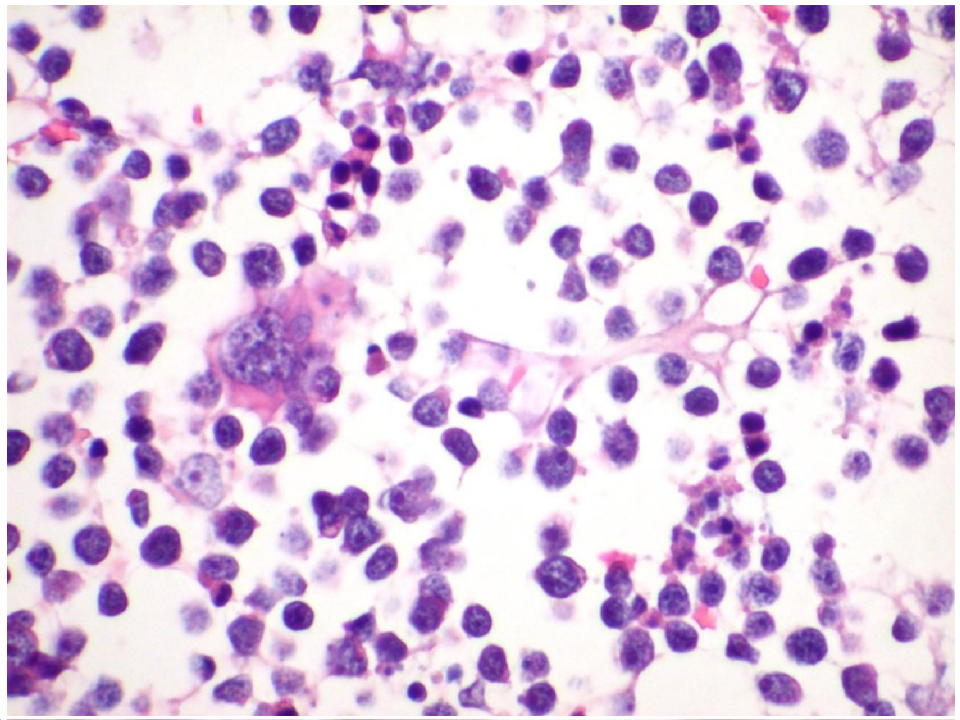
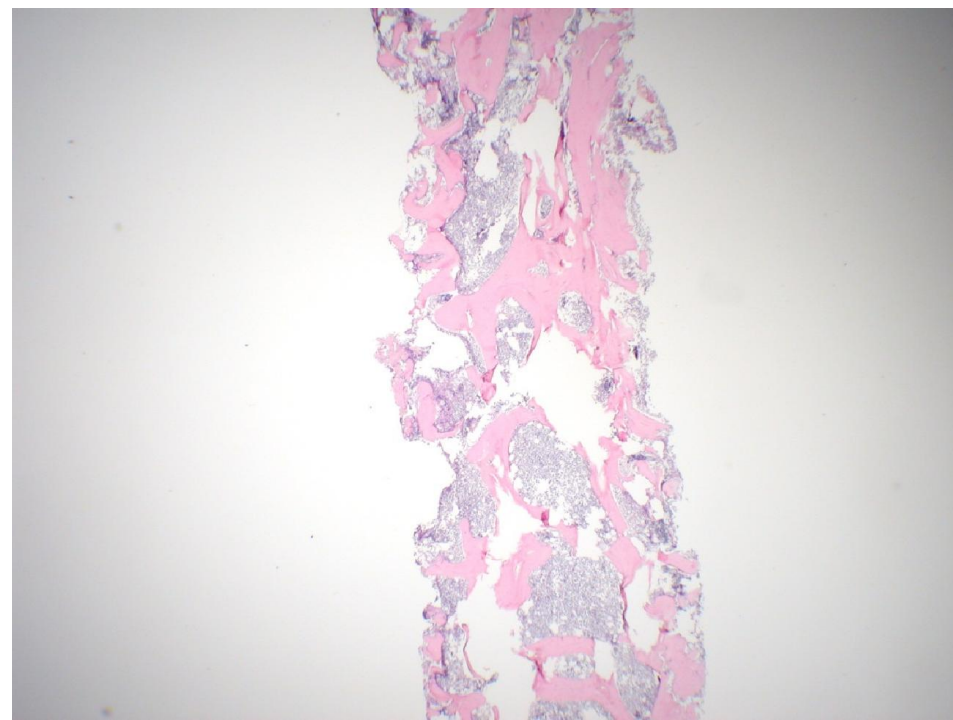
Dye/Sample Peak	Sample File Name	Marker	Allele	Size	Height	Area	Data Point
G,13	42_H05_015.fsa			211.16	3719	28462	3597
G,14	42_H05_015.fsa			211.75	3982	30885	3605
G,15	42_H05_015.fsa			239.36	133	851	3979

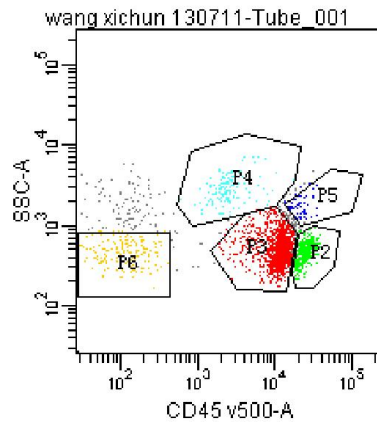
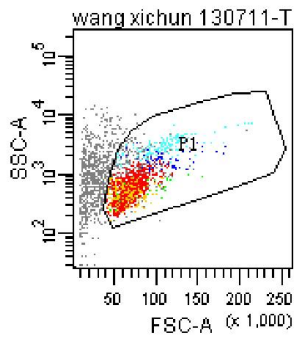






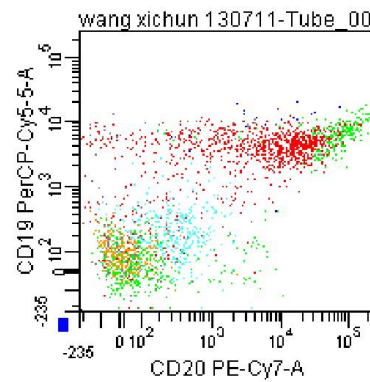
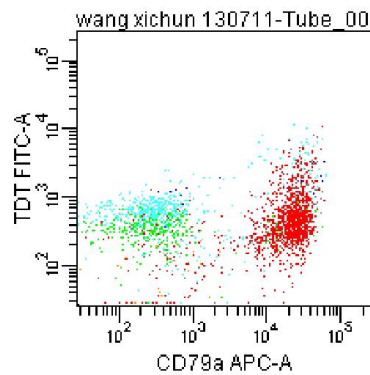
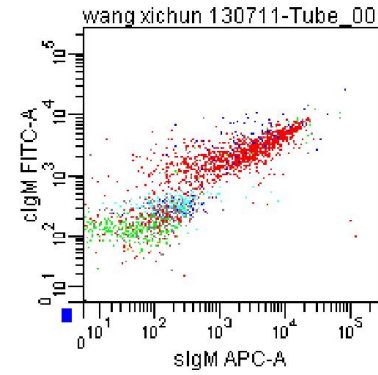
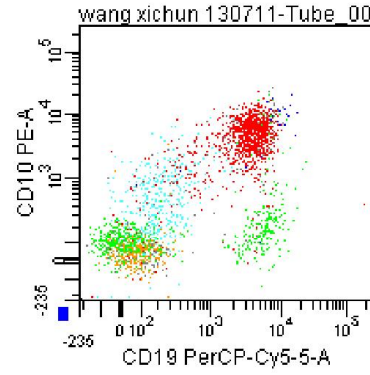
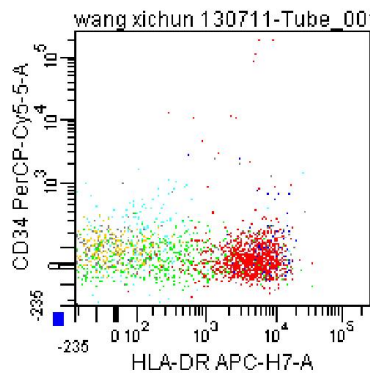
又被忽悠了!



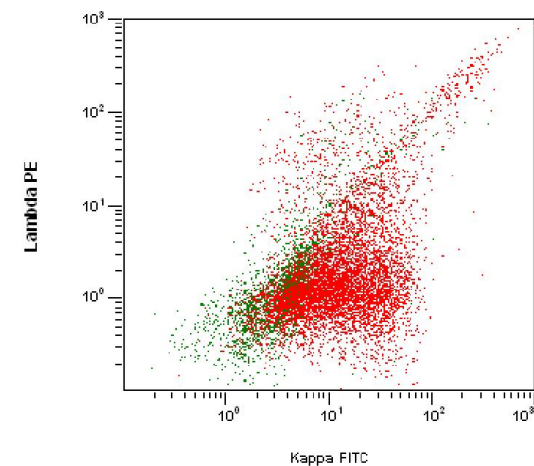


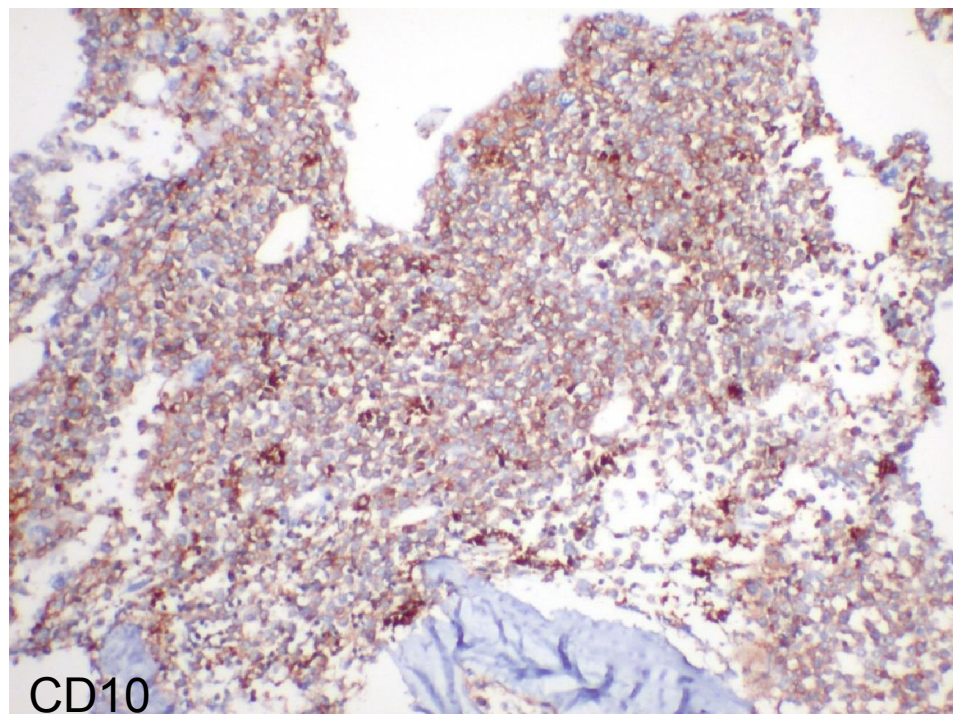
Tube: Tube_002

Population	#Events	%Parent	%Total
All Events	12,101	####	100.0
P1	9,567	79.1	79.1
P2	1,963	20.5	16.2
P3	4,793	50.1	39.8
P4	1,259	13.2	10.4
P5	35	0.4	0.3
P6	976	10.2	8.1

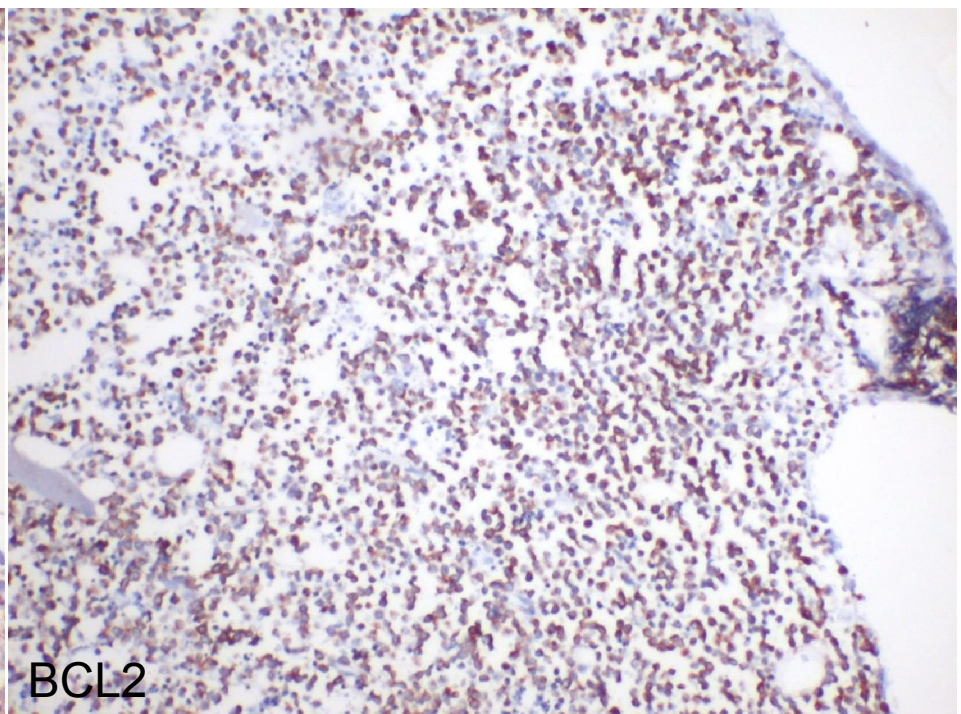


(F1)(A) wang xichun 2013-07-25 118.LMD : FL1 Log/FL2 Log - ADC

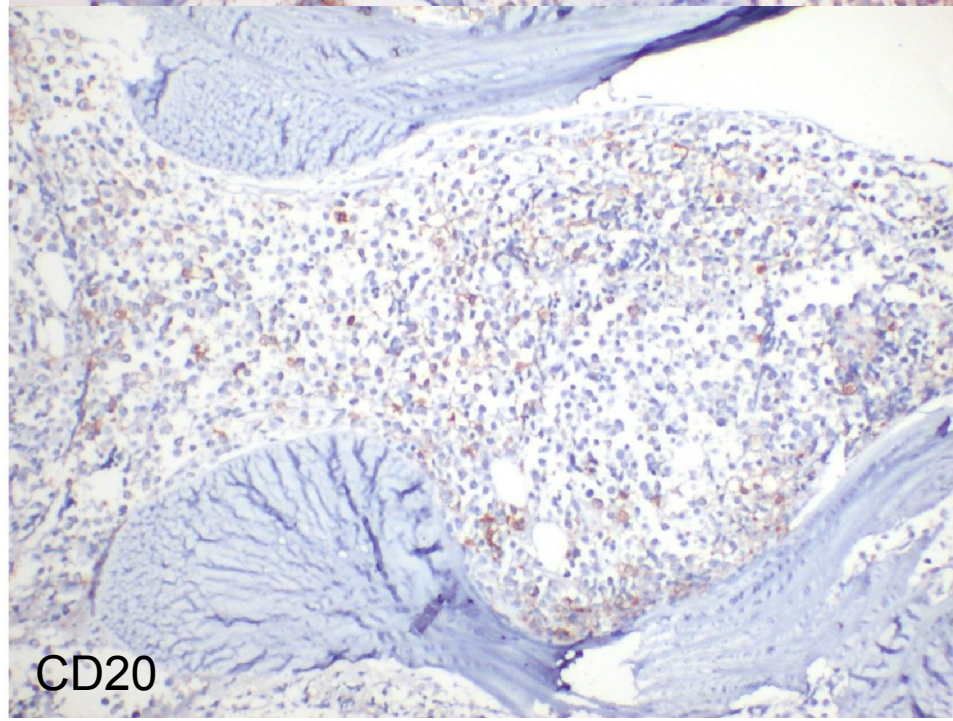




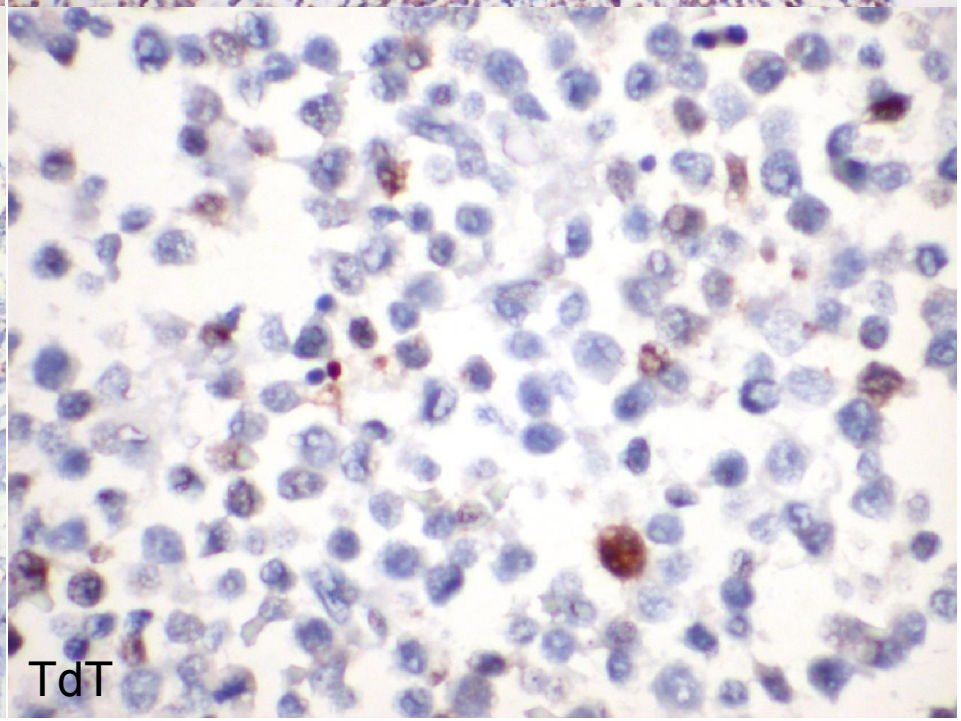
CD10



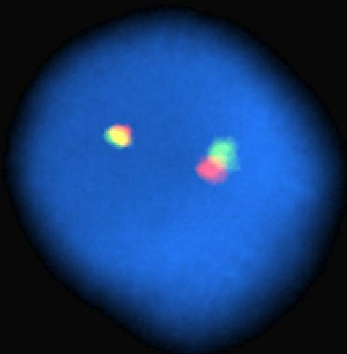

BCL2



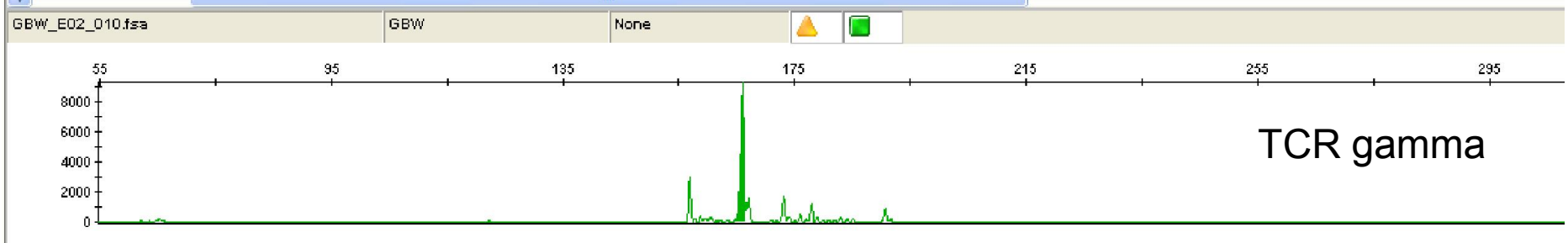
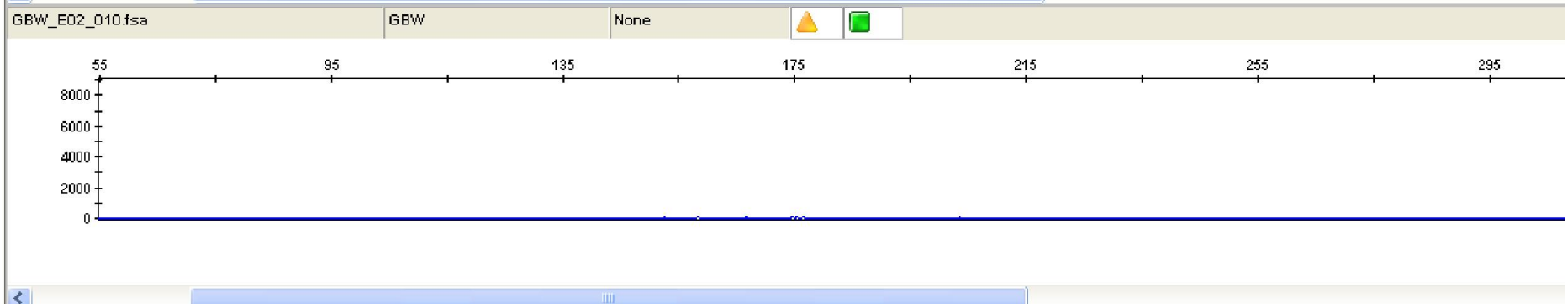
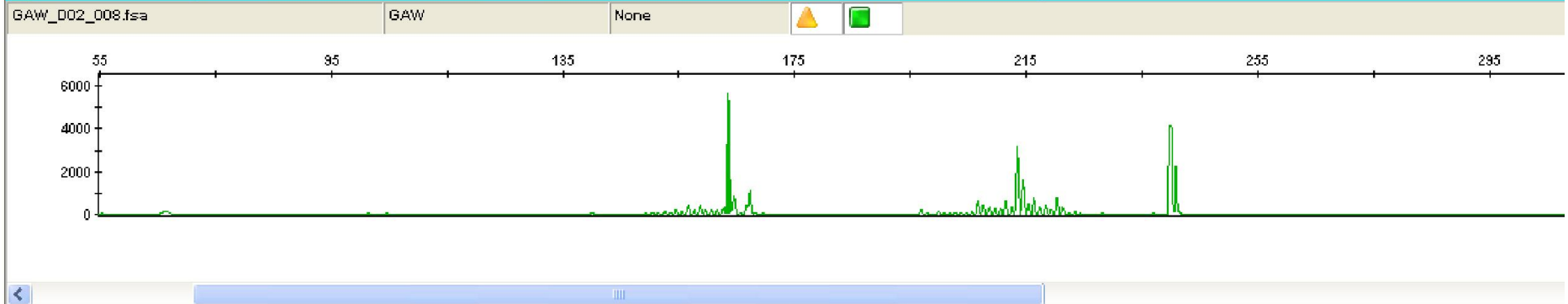
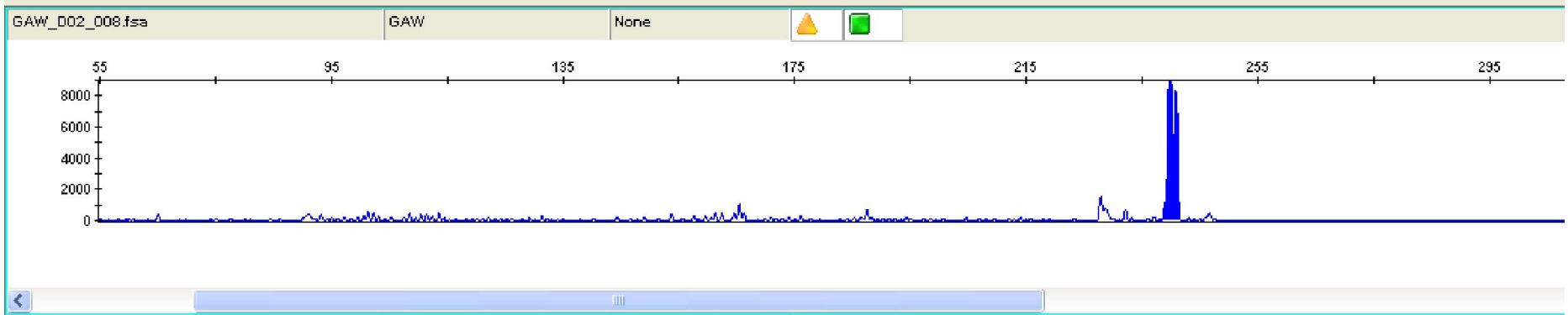
CD20



TdT



MYC departure probe






血液病理诊断报告

编号: 2013-5403

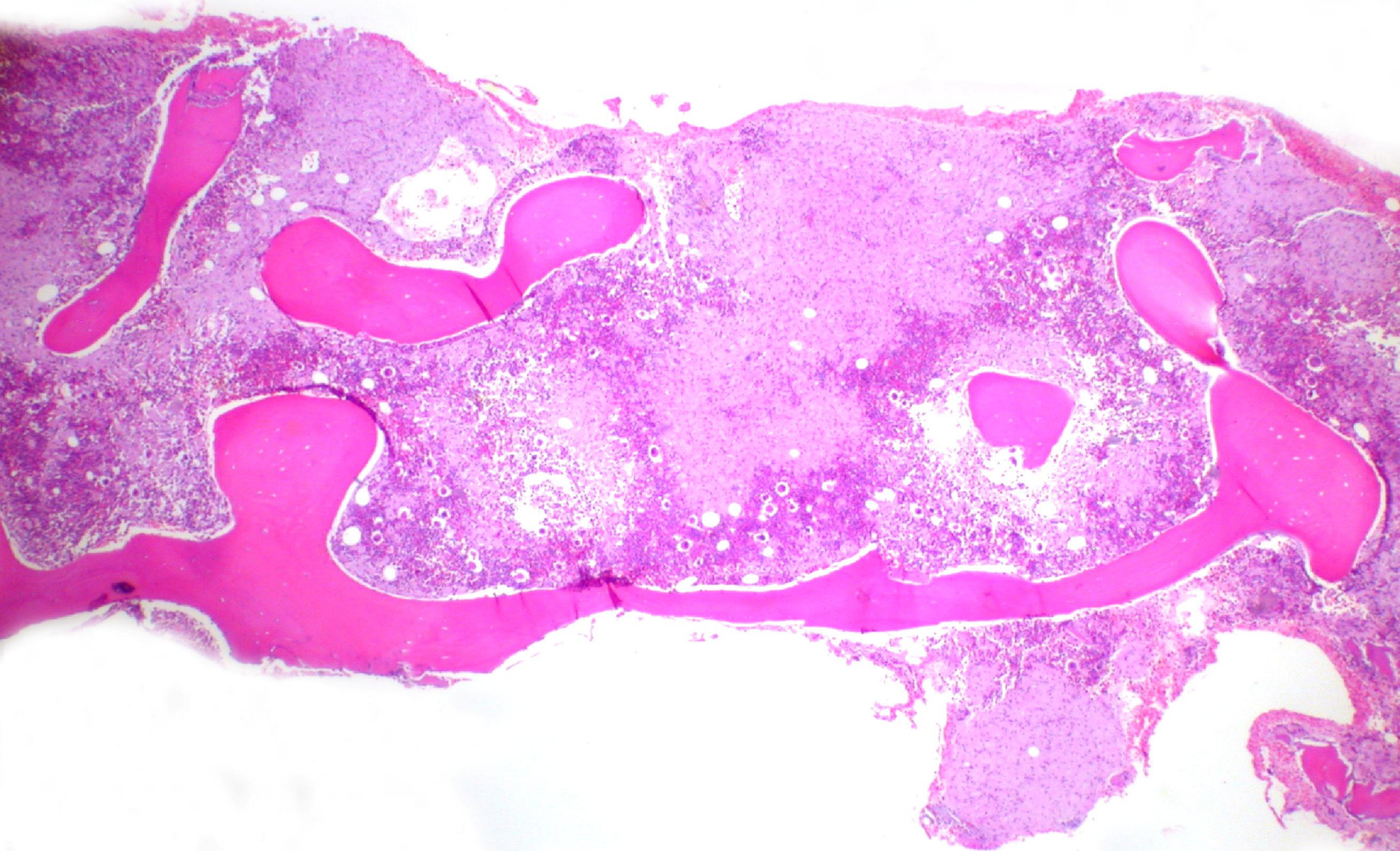
姓名:	性别: 男	年龄: 33 岁	科室: 白血病诊疗中心
病案号: 329153	采取部位: 髂骨	送检物: 骨髓	送检单位: 本院
临床诊断: 急性淋巴细胞白血病	送检医生: 易树华	送检日期: 2013.7.17	

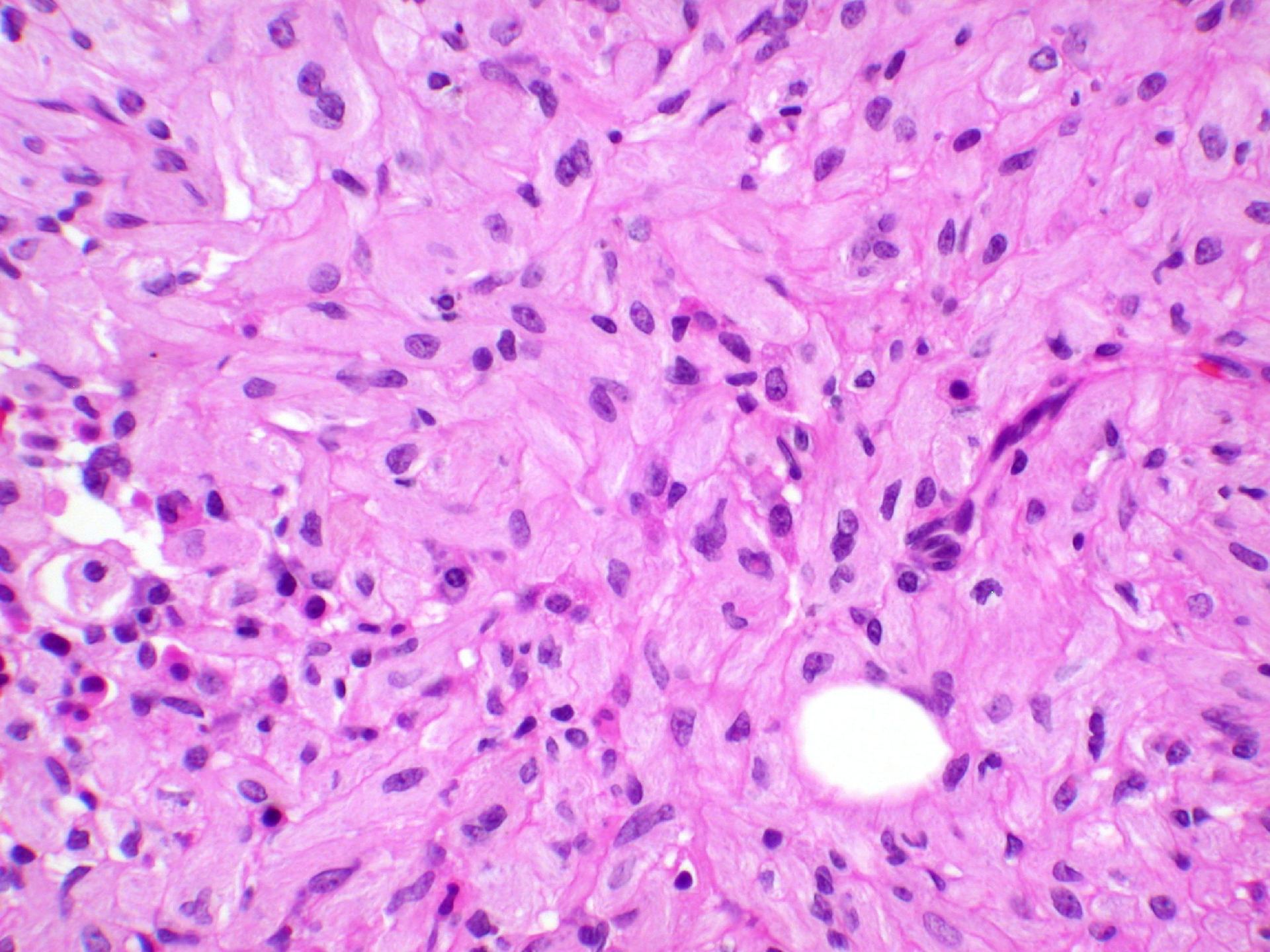
诊断: 侵袭性 B 细胞白血病/淋巴瘤, 见总结。

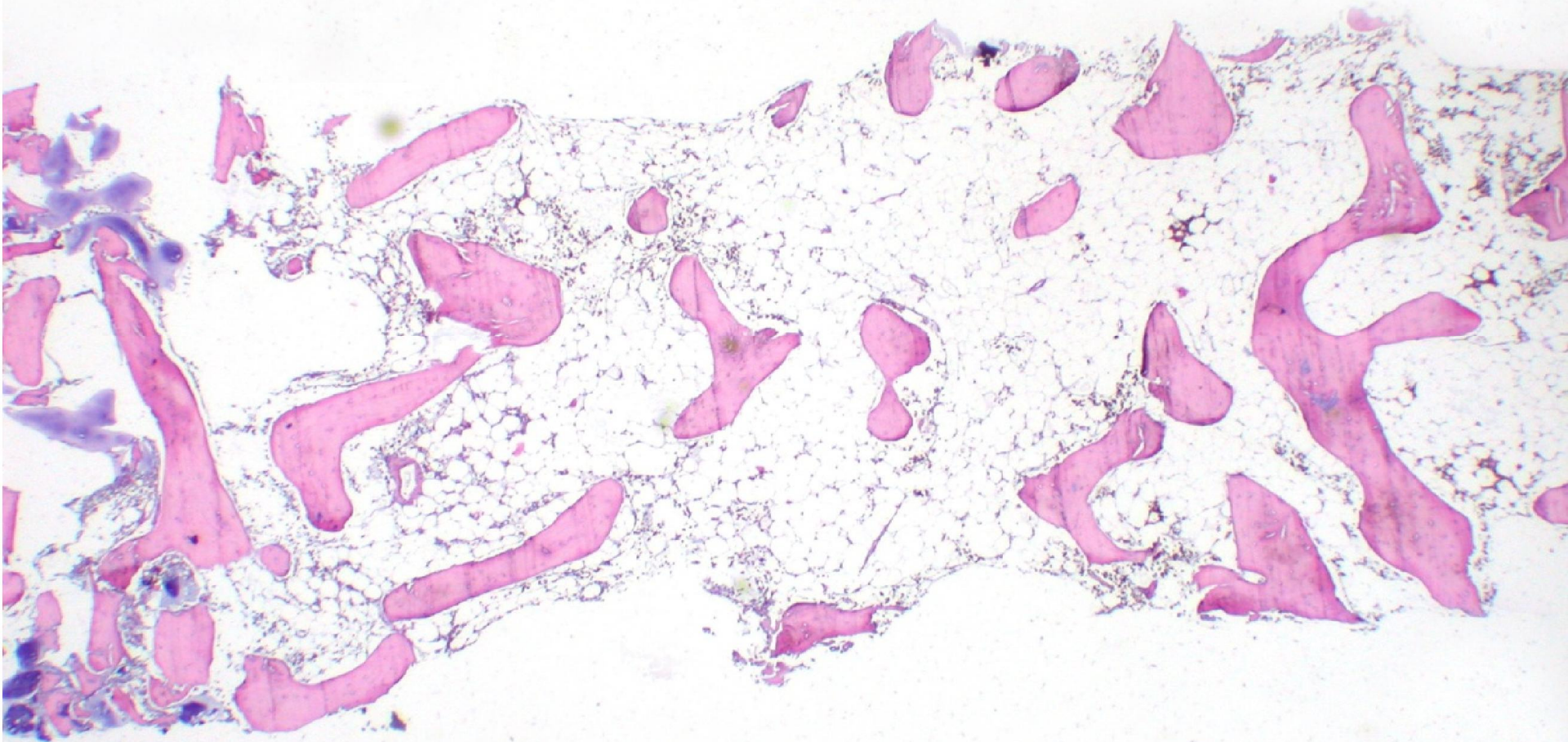
总结: 该肿瘤具有 B 细胞肿瘤的不典型特点, 鉴别诊断包括 Burkitt 淋巴瘤 (BL) 和 B 原始淋巴细胞白血病 (B-ALL)。形态学、免疫分型中 BCL2 阳性和 TdT 部分阳性、MYC 突变阴性、TCR 克隆性改变、以及临床特点倾向于 B-ALL; 而流式细胞的免疫分型包括细胞表面 IgM 和 kappa 阳性则提示该细胞分化趋于成熟。综合各项检查结果, 倾向于分化晚期的 CD20 部分阳性的 B-ALL。

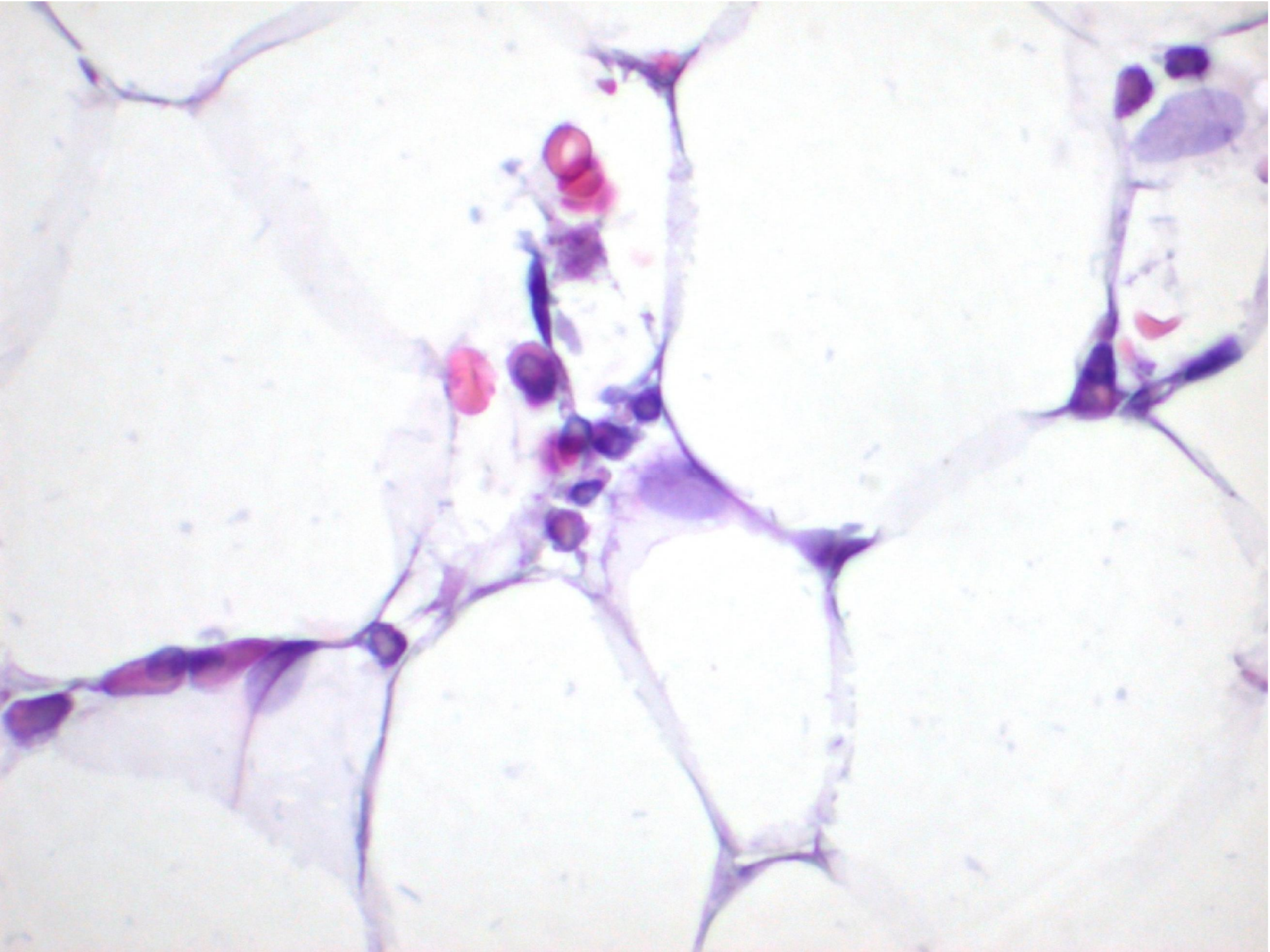


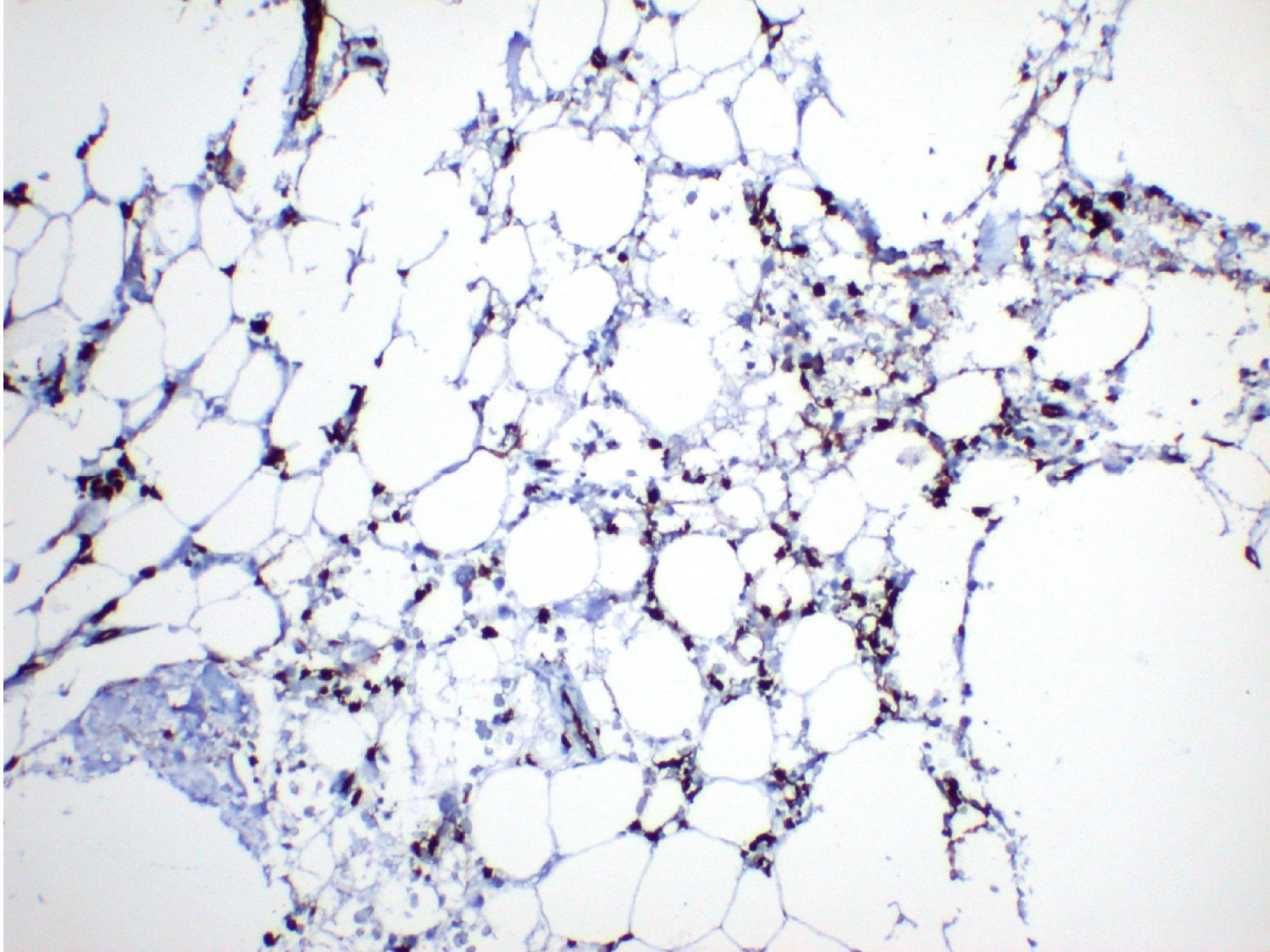
细
少
纤
包。

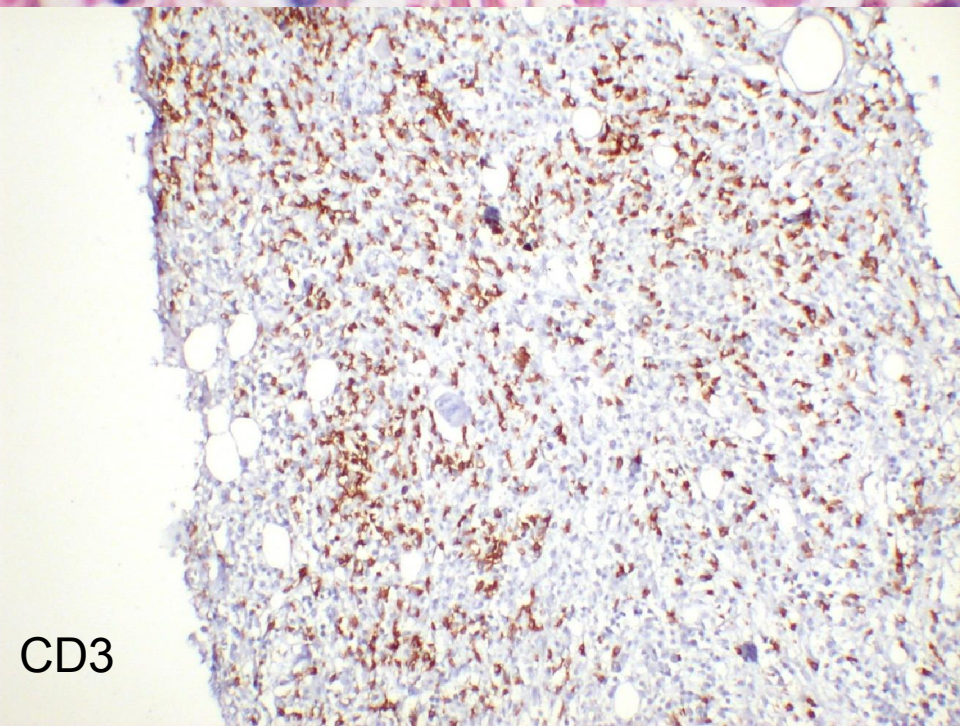
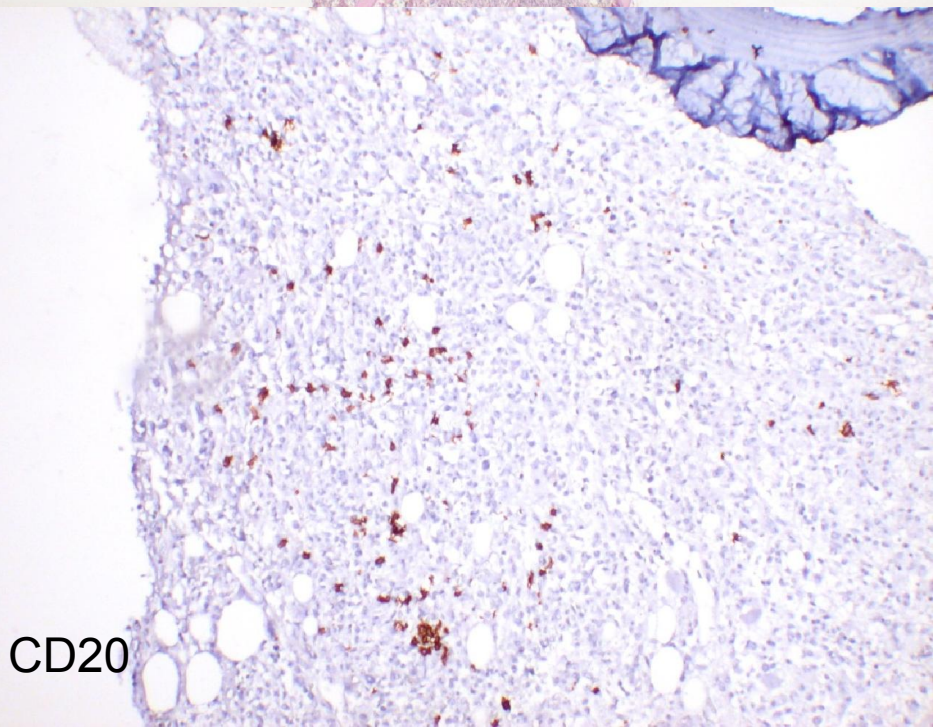
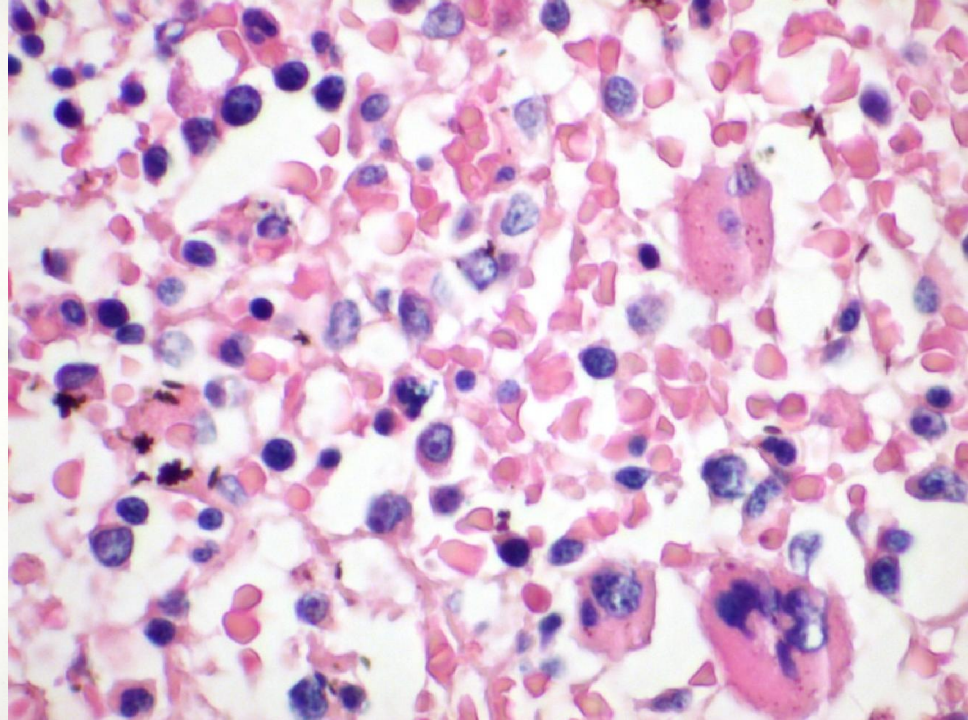
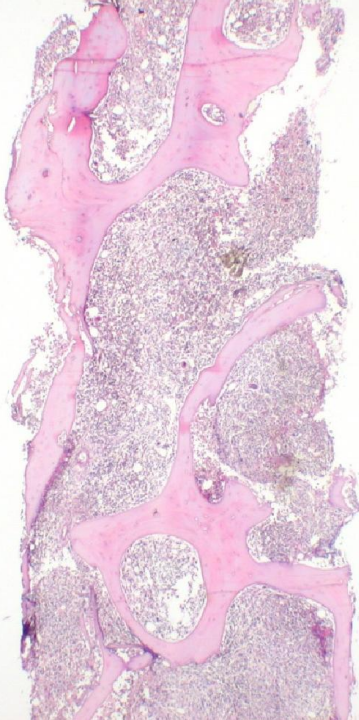


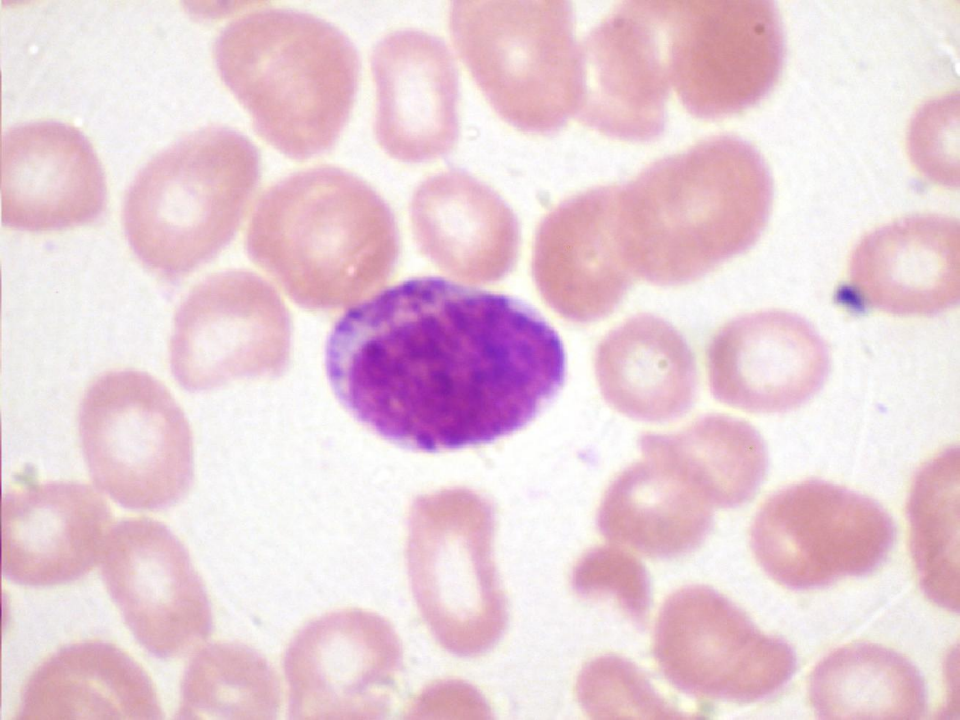
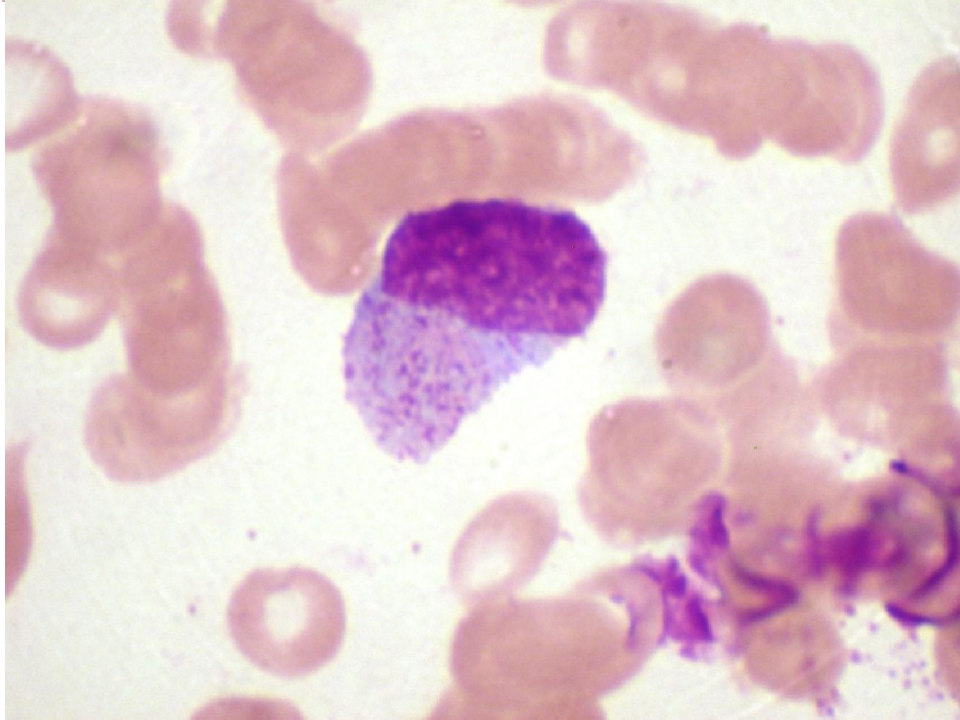
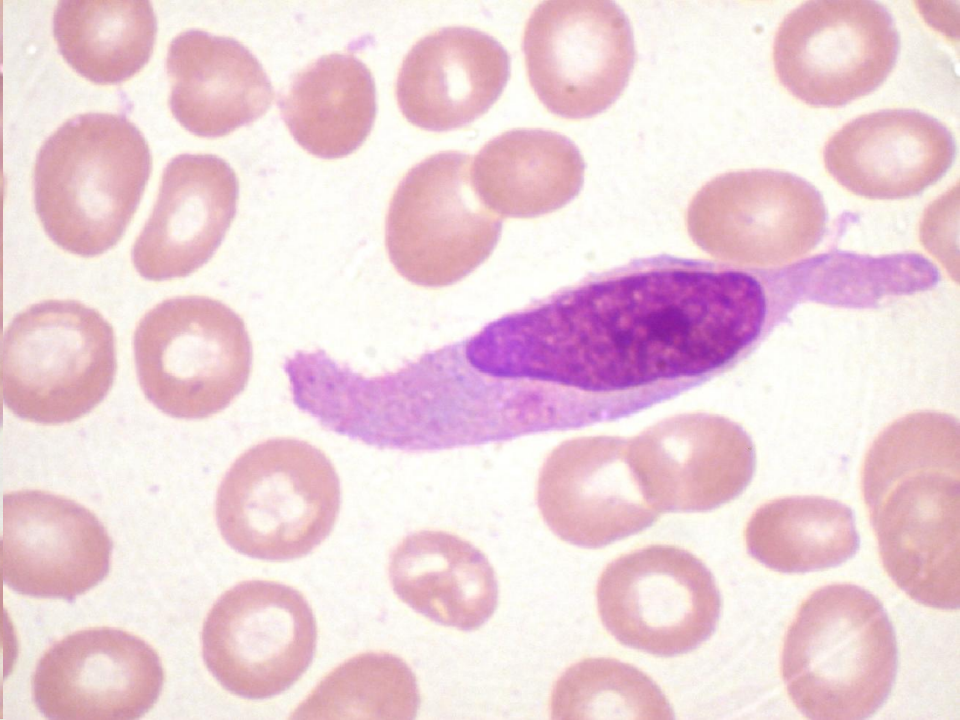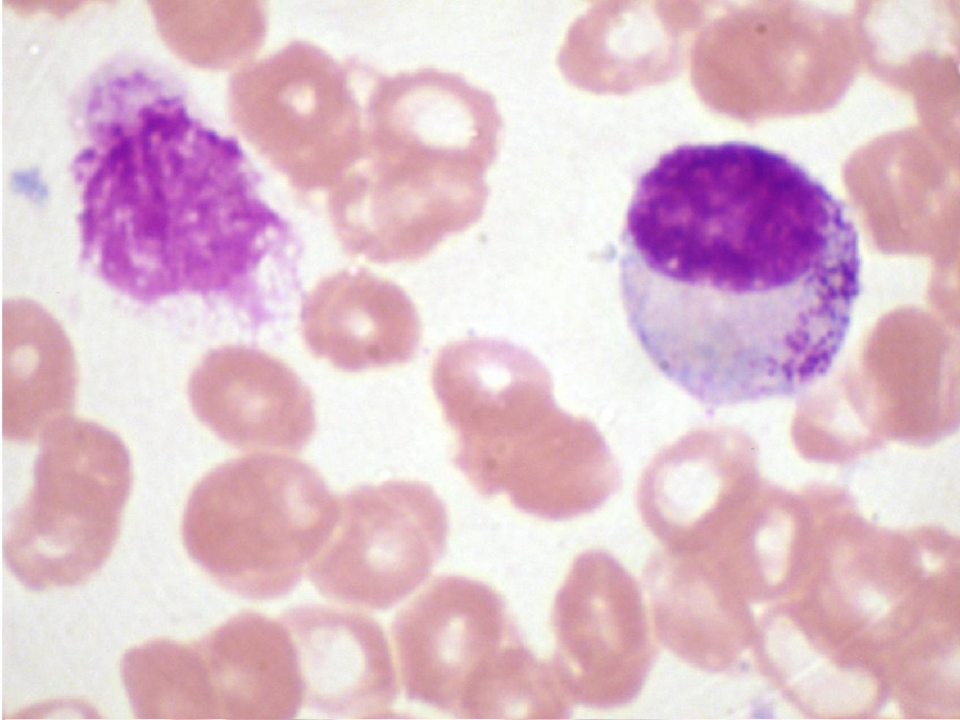








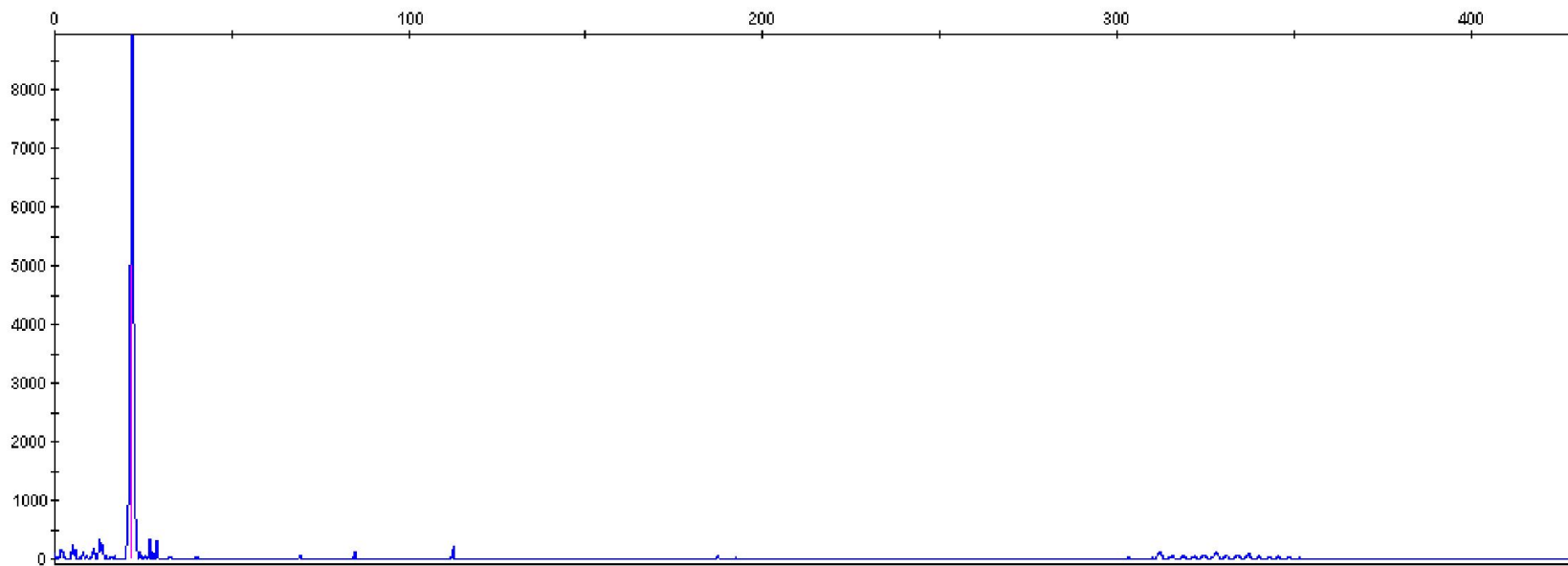




3_H03_015.fsa

8

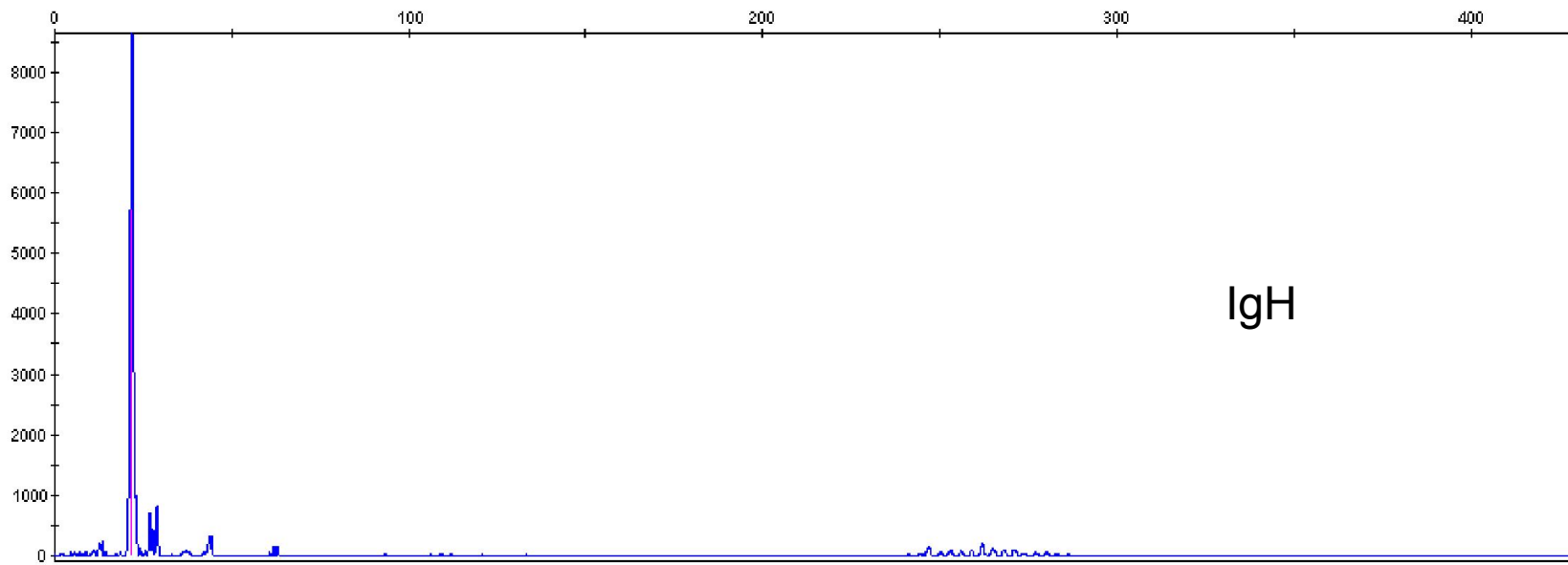

None



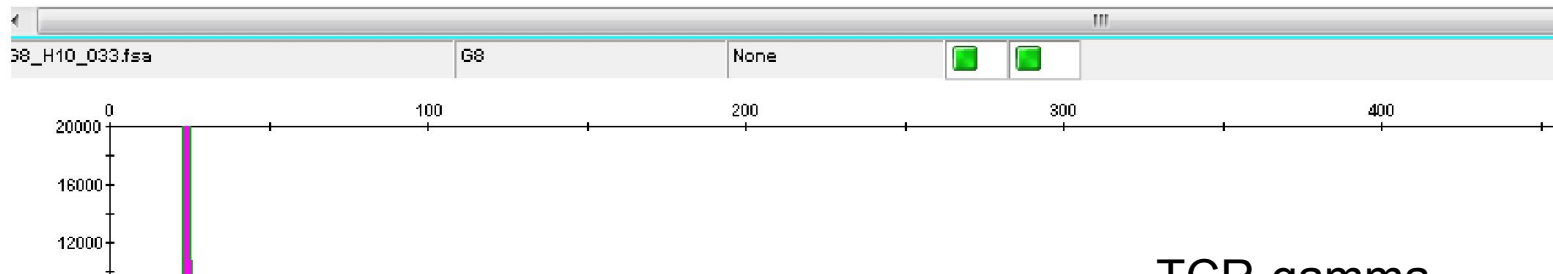
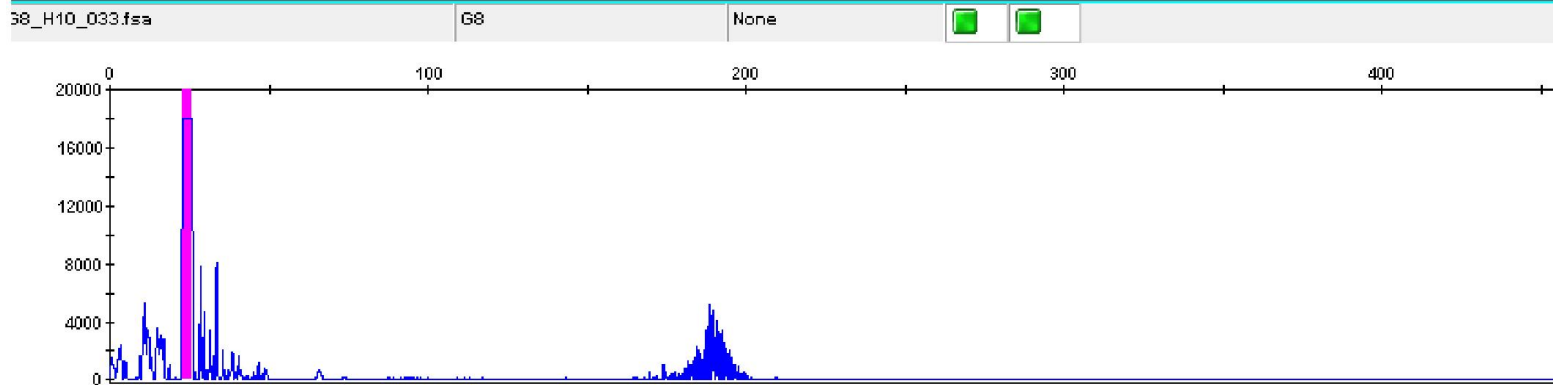
3_H04_016.fsa

8

None



IgH



TCR-gamma

